



RESEARCH ARTICLE

# Hepatoprotective potency of *Lagenandra toxicaria* and *Ariopsis peltata* against CCl<sub>4</sub> induced liver fibrosis in Wistar rats

Akarsha B<sup>1</sup>, Krishnakumar G<sup>1\*</sup> & Prasanna Shama Khandige<sup>2</sup>

<sup>1</sup> Department of Applied Botany, Mangalore University, Mangalore, Konaje– 574 199, India

<sup>2</sup> Department of Pharmacology, NGSM Institute of Pharmaceutical Sciences Nitte (Deemed to be University) Mangalore. Deralakatte– 575 018, India

\*Email: [kkgtaxo13@gmail.com](mailto:kkgtaxo13@gmail.com)

 OPEN ACCESS

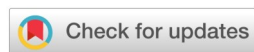## ARTICLE HISTORY

Received: 22 January 2022

Accepted: 02 August 2022

Available online

Version 1.0 : 10 September 2022



## Additional information

**Peer review:** Publisher thanks Sectional Editor and the other anonymous reviewers for their contribution to the peer review of this work.

**Reprints & permissions information** is available at [https://horizonepublishing.com/journals/index.php/PST/open\\_access\\_policy](https://horizonepublishing.com/journals/index.php/PST/open_access_policy)

**Publisher's Note:** Horizon e-Publishing Group remains neutral with regard to jurisdictional claims in published maps and institutional affiliations.

**Indexing:** Plant Science Today, published by Horizon e-Publishing Group, is covered by Scopus, Web of Science, BIOSIS Previews, Clarivate Analytics, NAAS etc. See [https://horizonepublishing.com/journals/index.php/PST/indexing\\_abstracting](https://horizonepublishing.com/journals/index.php/PST/indexing_abstracting)

**Copyright:** © The Author(s). This is an open-access article distributed under the terms of the Creative Commons Attribution License, which permits unrestricted use, distribution and reproduction in any medium, provided the original author and source are credited (<https://creativecommons.org/licenses/by/4.0/>)

## CITE THIS ARTICLE

Akarsha B, Krishnakumar G, Khandige P S . Hepatoprotective potency of *Lagenandra toxicaria* and *Ariopsis peltata* against CCl<sub>4</sub> induced liver fibrosis in Wistar rats. Plant Science Today (Early Access). <https://doi.org/10.14719/pst.1691>

## Abstract

*Lagenandra toxicaria* (LT) and *Ariopsis peltata* (AP) belongs to the family Araceae. LT is being traditionally used to cure bilious symptoms and wound healing. AP leaves are edible and the rhizome has medicinal value. With such a wide range of medicinal applications, it's essential to scientifically authenticate traditional usage and find the plant's bioactive components. Here, we have examined the anti-inflammatory and hepatoprotective potency of these plant extracts. The *in-vivo* liver fibrosis was induced in Wistar male rats using CCl<sub>4</sub> and was treated with various concentrations of the methanol and water extracts of the plant rhizomes. In the *in-vitro* anti-inflammatory assay, LT methanol extract showed 42 % protection at 600 mg/ml which is higher than the other extracts. Among the AP and LT extracts, the 600 mg/kg methanol extract of LT treated rats showed a decreased ( $p < 0.05$ ) serum alanine/aspartate aminotransferase and total bilirubin levels. The plant extract brought about an amelioration of CCl<sub>4</sub> induced pathological effects and a significant reduction in the severity of inflammation, fatty metamorphosis, necrosis and liver fibrosis. Overall, the results suggest that LT rhizome could be effective in the treatment of liver fibrosis. It is possible that this is related to the presence of anti-inflammatory and antioxidant chemicals such as 9-octadecenamide, flavonoids and phenols in the extract.

## Keywords

*Lagenandra toxicaria*, *Ariopsis peltata*, GC-MS, Liver fibrosis, anti-inflammatory

## Introduction

Liver is a major organ that regulates various physiological functions and about 500 essential tasks are attributed to the liver (1). Hence, damage or loss of any liver function can have serious effects on our health. According to recent statistics, liver illnesses kill over two million people each year throughout the world. Cirrhosis complications account for almost one million deaths (2). Repeated liver injury by toxicants, synthetic drugs, or hepatic viruses cause sustained inflammation resulting in the accumulation of excess extracellular matrix (ECM) which leads to the fibrosis of the liver tissue. The accumulated ECM proteins damage the liver by forming a fibrous scar leading to liver cirrhosis and cancer (3, 4). The management of inflammation, oxidative damage, apoptosis and related tissue responses are the essential therapeutic strategies for preventing liver failure (5, 6). Herbal medications have recently acquired attention due to their anti-fibrotic qualities as well as other benefits such as low side effects, low toxicity and low

cost. For the treatment of liver disorders, 65 % of patients in Europe and the United States rely on herbal remedies (6). Many phytochemicals such as silymarin, armepavine, salvianolic acid, plumbagin, rhein, glycyrrhetic acid, epigallocatechin-3-gallate, osthole and curcumin have been isolated, recorded, and thoroughly researched for their efficacy in treating liver fibrosis (4). The plant constituents have anti-inflammatory and antioxidant properties that can have multiple effects in counteracting liver fibrosis and recovering the damaged cells (7). Among the Araceae members, several plants were reported for their hepatoprotective activity. According to one report (8) *Colocasia esculenta* corm ethanolic extract showed significant hepatoprotective activity against CCl<sub>4</sub> and paracetamol-induced liver damage compared to silymarin. Similarly, the ethanolic and methanolic extracts of *Amorphophallus campanulatus* corm could restore the CCl<sub>4</sub> induced hepatic damage and reduce ALT, AST and ALP (7). Quercetin, extracted from the ethyl acetate fraction of *A. paeoniifolius* corm was reported to have a hepatoprotective effect against CCl<sub>4</sub> induced hepatotoxicity (9). Study showed that *Alocasia macrorrhiza*, exhibits anti-inflammatory potency against carrageenan-induced paw oedema in rats and further it also shows hepatoprotective and anti-inflammatory activity (10). It is crucial that ethnomedicinally beneficial plant's efficacy toward liver therapy has to be scientifically evaluated. The present study examined the antioxidant, anti-inflammatory and hepatoprotective activities of the rhizome extracts of two plants of Araceae viz. *Lagenandra toxicaria* and *Ariopsis peltata*. *Lagenandra toxicaria* is traditionally used for treating bilious complaints and wound healing (11). *Ariopsis peltata* leaves are edible and rhizomes are used indigenously to treat bilious complaints (12).

## Materials and Methods

### Reagents

Alanine aminotransferase (ALT), Aspartate aminotransferase (AST) and Total bilirubin (TBL) analysis kits were purchased from Agappe diagnostics Pvt. Kerala, India. Hydrogen peroxide and CCl<sub>4</sub> were purchased from NICE, Kerala, India. All other reagents used were of analytical quality.

### Plant collection

*Lagenandra toxicaria* and *Ariopsis peltata* rhizomes were collected from Markanja village, Sullia taluk (12°34'38.7" N, 75°29'54.8" E) and Charmadi ghat in Belthangadi taluk of Dakshina Kannada District (13°04'35" N, 75°27'06" E), Karnataka, India. Plants were identified and the voucher specimens were deposited in the herbarium of the Department of Applied Botany (AK08 & AK09), Mangalore University. The plant rhizomes were washed in running tap water and air-dried, powdered and stored for further study.

### Preparation of extract

Using the soxhlet apparatus and a water bath, 25 g of dried rhizome powder was extracted in 250 ml of methanol and water. The extracts were vacuum dried at 45 °C and stored at 4 °C for further use (13). The percentage yield was measured using the formula (Eqn 1).

ured using the formula (Eqn 1).

$$\% \text{ yield} = \frac{\text{weight of the extract}}{\text{weight of the dried sample taken}} \times 100$$

Eqn. 1

### Analysis of total phenolic and flavonoid content

The total phenol and flavonoid content of the extract was analyzed using Gallic acid and Quercetin standards respectively by spectrophotometry method (14).

### Antioxidant analysis

Antioxidant properties were analyzed using Ferric reducing antioxidant power (FRAP) assay and DPPH assay. DPPH solution was prepared using methanol. One ml of different concentrations of plant extracts (0.1 to 1 mg/ml) was added to the DPPH solution. The reaction mixture was vortexed and kept for incubation in dark, at room temperature and the absorbance was measured at 517 nm. The IC<sub>50</sub> of the plant extract was determined (15) using the formula (Eqn. 2).

1 ml of the extract (0.1 to 1 mg/ml) was mixed with 2.5 ml of phosphate buffer (0.2 mol, pH 6.6) and 2.5 ml of 1 % potassium ferricyanide and incubated at 50 °C for 20 min. Then added 2.5 ml of 10 % trichloroacetic acid and centrifuged for 10 min at 3000 rpm. From each tube, 2.5 ml of supernatant was collected and diluted twice with distilled water, 0.5 ml of freshly prepared FeCl<sub>3</sub> solution (0.1%) was added to the diluted mixture, the absorbance was measured at 700 nm (15).

$$\% \text{ DPPH radical scavenging activity} = \frac{(\text{OD control} - \text{OD sample})}{\text{OD control}} \times 100$$

Eqn. 2

### In-vitro Anti-inflammatory analysis using human blood

The anti-inflammatory activity of the extracts was examined by HRBC (Human red blood cells) membrane stabilization method. Five millilitres of blood was obtained from a healthy human volunteer in a sterile tube and used for the experiment, following the standard protocol (16). Diclofenac was used as the standard drug and the control was without the extracts. At 560 nm, the absorbance of the supernatant was measured using a spectrophotometer. The % of hemolysis was calculated by assuming that 100 % hemolysis occurred in the control. The following formula (Eqn. 3) was used to determine the percentage of hemolysis.

$$\% \text{ of protection} = 100 - (\text{OD test sample} / \text{OD of control}) \times 100$$

Eqn. 3

### Animals and experiment

NUCARE (Nitte University Centre for Animal Research and Experimentation), Deralakatte, Mangalore, provided female *Mus musculus* mice weighing 25-30 g and Wistar male rats weighing 180-200 g. The animals were maintained at a constant temperature of 22 °C, with 12 hr of darkness and

12 hr of light. The animals were fed with conventional laboratory food and had access to clean water. The animal experiments were approved by the Nitte Institute's animal ethical committee, with the protocol number (NGSMIPS/IAEC/MARCH-2019/124).

#### Acute toxicity study

Test No. 423 (OECD, 2001; Acute oral toxicity - acute toxic class technique) was used to conduct an acute oral toxicity study following OECD rules for chemical testing. The study involved 5 animal groups, each group containing 6 animals that are randomly assigned. The animals were fasted for 3-4 hr and the plant extract was administered with an initial dose of 2000 mg/kg body weight (B. W). The treated animals were observed for 14 d and if two out of 3 animals died then the dose was considered toxic. If one out of 3 animals is dead then the same dose was repeated for its toxicity confirmation and if the mortality is observed again then the experiment was repeated with lower doses of the extract.

#### Induction of liver fibrosis

The male Wistar rats weighing 180-210 g were procured and housed in a suitable environment following the OECD guidelines. All animal experiments were carried out following the procedure of the Institutional Animal Care and Use Committee of Nitte Deemed to be University for the care and use of laboratory animals. The experimental design involved 12 groups containing n = 8 animals in each group.

Group 1: Normal control + saline

Group 2: Positive control (CCl<sub>4</sub> + Olive oil (1:1 1 ml/kg B.W) twice a week (t.w))

Group 3: Negative control (CCl<sub>4</sub> + 0.1 % DMSO)

Group 4: CCl<sub>4</sub> (t.w) + Silymarin 100 mg/kg

Group 5: CCl<sub>4</sub> (t.w) + *Lagenandra toxicaria* methanol extract (LM6) 600 mg/kg

Group 6: CCl<sub>4</sub> (t.w) + *Lagenandra toxicaria* methanol extract (LM4) 400 mg/kg

Group 7: CCl<sub>4</sub> (t.w) + *Lagenandra toxicaria* water extract (LW6) 600 mg/kg

Group 8: CCl<sub>4</sub> (t.w) + *Lagenandra toxicaria* water extract (LW4) 400 mg/kg

Group 9: CCl<sub>4</sub> (t.w) + *Ariopsis peltata* methanol extract (AM6) 600 mg/kg

Group 10: CCl<sub>4</sub> (t.w) + *Ariopsis peltata* methanol extract (AM4) 400 mg/kg

Group 11: CCl<sub>4</sub> (t.w) + *Ariopsis peltata* water extract (AW6) 600 mg/kg

Group 12: CCl<sub>4</sub> (t.w) + *Ariopsis peltata* water extract (AW4) 400 mg/kg

CCl<sub>4</sub> was given twice a week at an interval of 3 d. The standard drug silymarin and the plant extracts were administered every day for 8 weeks (17). After eight weeks of treatment, the animals were sacrificed by cervical dislocation. The blood samples were collected and used for serum enzyme analysis. The liver tissues were isolated and a

portion was stored in formalin for histopathological studies. The remaining tissues were homogenized (10%, w/v) in 50 mM phosphate buffer (pH. 7.0) and stored at -80 °C for testing.

#### Liver index calculation

The body weight and liver weight of each animal was recorded and the liver index of the rats was calculated using the formula (Eqn. 4) followed by standard procedure (18).

$$\text{Liver index} = \frac{\text{Liver weight}}{\text{Body weight}} \times 100$$

Eqn. 4

#### Examination of serum ALT, AST and Total bilirubin activities

The serum was isolated from collected blood samples and the levels of serum AST, ALT and total bilirubin activities were examined by Agappe kits (India) using semi auto-analyzer (STAR 21) following the maker's guidelines.

#### Liver histology examination

In a 10 % buffered formalin solution, a piece of the liver tissue was fixed, dehydrated in a 50-100 % ethanol series, cleaned in xylene and paraffin-embedded. The paraffin-embedded tissues were sectioned (5 mm) and stained with hematoxylin-eosin (H&E) for histological observation of liver injury and Masson's trichrome for observation of collagen deposition in the liver (19). 0 - 3 scoring system (grade 0 - absent, grade 1 - present in one-third of the lobule, grade 2 - present in two-third of the lobules, grade 3 - present in all the lobules) was used to indicate the level of necrosis, inflammation and fatty metamorphosis. For fibrosis, collagen was graded (20) grade 0 - normal, grade 1 - fibrosis present (collagen fiber present as small septa) grade 2 - mild fibrosis (collagen fiber extended as septa from portal tract to central vein forming complete septa); grade 3 - moderate fibrosis (collagen fibers formed thin complete septa) and grade 4 - severe fibrosis (collagen fibers formed thick septa). All histological assessments were carried out by a skilled operator who was blinded to the study.

#### Examination of lipid peroxidation and antioxidant enzyme

Isolated liver tissues were washed with chilled saline solution to remove the blood cells. A 10 % tissue homogenate was prepared and the supernatant was collected to determine the malondialdehyde (MDA) levels and catalase activity of the liver was calculated using hydrogen peroxide as a standard following standard methods (21).

#### Bioactive compound examination using GC-MS

*Lagenandra toxicaria* rhizome methanol extract was analyzed using GC-MS instrument, Shimadzu QP-2010 ultra. The oven temperature was retained at 60 to 280 °C at a speed of 10 °C per min. The injector volume was 1 µl and the split ratio was 10. The bioactive compounds were identified using the Willey/NIST mass spectral library of the GC-MS data system. The % composition of the different components of the sample was calculated from the peak area integrated by the analysis program.

## Statistical analysis

The data are presented as mean with  $\pm$  standard deviation. To investigate and compare the data, one-way ANOVA was performed, followed by Newman-Keuls multiple comparison tests (PRISM GraphPad, version 5.0; GraphPad Software Inc., San Diego, CA).

## Results

### Yield of extracts

The *Lagenandra toxicaria* and *Ariopsis peltata* showed yield of 12.1 % and 12.6 % in methanol and 14.8 % and 17.2 % in water respectively.

### Phenolic and flavonoid content analysis

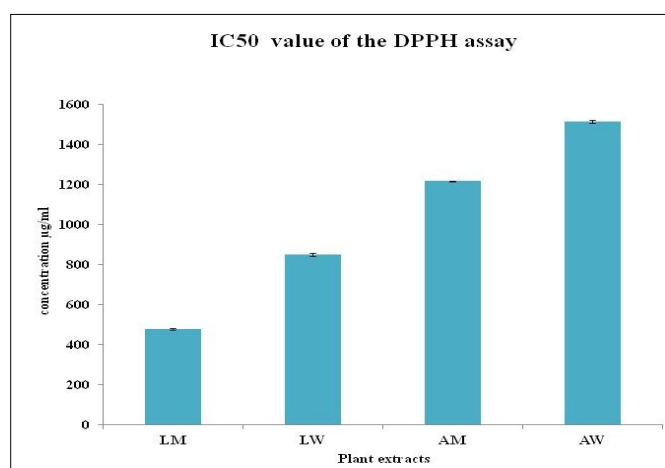
The phenolic and flavonoid content of the plant extracts is given in Table 1. The methanol extract of both the plants had higher phenol and flavonoid content. Both the methanol and water extract of *L. toxicaria* was rich in phenolics and flavonoids. Water extract of *A. peltata* had lower content.

**Table 1.** Phenolic and flavonoid content of the plant extracts

	Total phenol mg GE/g	Flavonoid mg QE/g
<i>Lagenandra toxicaria</i> methanol extract	65.19 $\pm$ 1.82	39.07 $\pm$ 1.98
<i>Lagenandra toxicaria</i> water extract	57.34 $\pm$ 2.46	25.74 $\pm$ 2.27
<i>Ariopsis peltata</i> methanol extract	55.23 $\pm$ 3.53	24.57 $\pm$ 1.20
<i>Ariopsis peltata</i> water extract	30.73 $\pm$ 4.34	13.97 $\pm$ 2.12

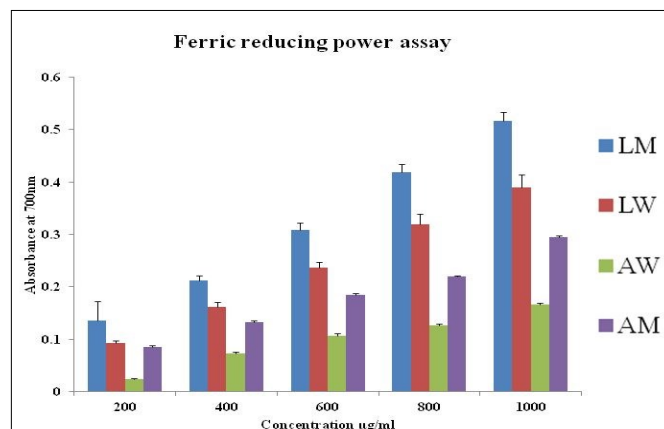
### Antioxidant assay

*L. toxicaria* methanol extract had an antioxidant activity of  $477.57 \pm 3.75$   $\mu$ g/ml which is higher compared to that of the water extract, ie,  $851.53 \pm 7.69$   $\mu$ g/ml. The antioxidant activity in *A. peltata* rhizome methanol and water extract was  $1216.62 \pm 6.61$   $\mu$ g/ml and  $1512.82 \pm 10.62$   $\mu$ g/ml (Fig. 1a). The reducing power of all the extracts increased with



**Fig. 1a.** Antioxidant activity of the plant extracts using DPPH reducing power assay.

increase in concentration as evidenced by the increased absorbance at 700 nm. The *L. toxicaria* methanol extract had the highest reducing power, with a higher absorbance at 1000  $\mu$ g/ml than the other extracts. *A. peltata* water extracts showed lower absorbance compared to the other extracts (Fig. 1B).



**Fig. 1b.** Antioxidant activity of the plant extracts using Ferric reducing antioxidant power assay.

### Anti-inflammatory activity

Inhibition of hemolysis by the plant extracts was analyzed using the human red blood cells. Both the plant extracts showed stabilization of HRBC at different concentrations (200 mg/ml, 400 mg/ml, 600 mg/ml and 800 mg/ml). The *L. toxicaria* methanol extract showed more protection compared to all other extracts. At 400 mg/ml it showed  $31.19 \pm 6.09$  % of protection and at 600 mg/ml, it showed  $41.99 \pm 3.32$  % of protection against hemolysis. At higher concentrations, the protection was decreased. The results are represented in Table 2.

### Acute toxicity study

The methanol and water extracts of both the plants at 2000 mg/kg dose did not show any behavioural changes or mortality in treated animals. Hence, the extracts were considered to be nontoxic.

### Body weight and liver index

In the positive and negative control groups the body weight decreased significantly ( $p < 0.05$ ) compared to the normal control group. A mortality of two animals each were seen in these 2 groups. The extract and silymarin treated group did not show any mortality except for the 400 mg/kg *A. peltata* water extract where one animal was dead. A significant increase in body weight was seen in the *L. toxicaria* extract treated groups. The liver weight and liver index increased significantly in the positive control group compared to the normal control group. The liver weight and index decreased significantly in the standard control and in all the extract treated groups Table 3.

### Serum markers of CCl<sub>4</sub> induced liver fibrosis in animals

The concentrations of AST, ALT and TBL are good indicators of liver health. An increase in these enzymes is suggestive of abnormal liver function. In this study, higher levels of AST, ALT and TBL were observed in the positive control groups. The concentration of AST, ALT and TBL levels in different treatment groups is given in Fig. 2. Among the extract-treated groups, the 600 mg/kg *L. toxicaria* methanol extract showed the concentrations comparable to normal control group.

### Liver histology observation

The H&E staining (Fig. 3a) showed prominent hepatic steatosis, necrosis, infiltration of inflammatory cells, hepato

**Table 2.** Anti-inflammatory activity of the plant extracts

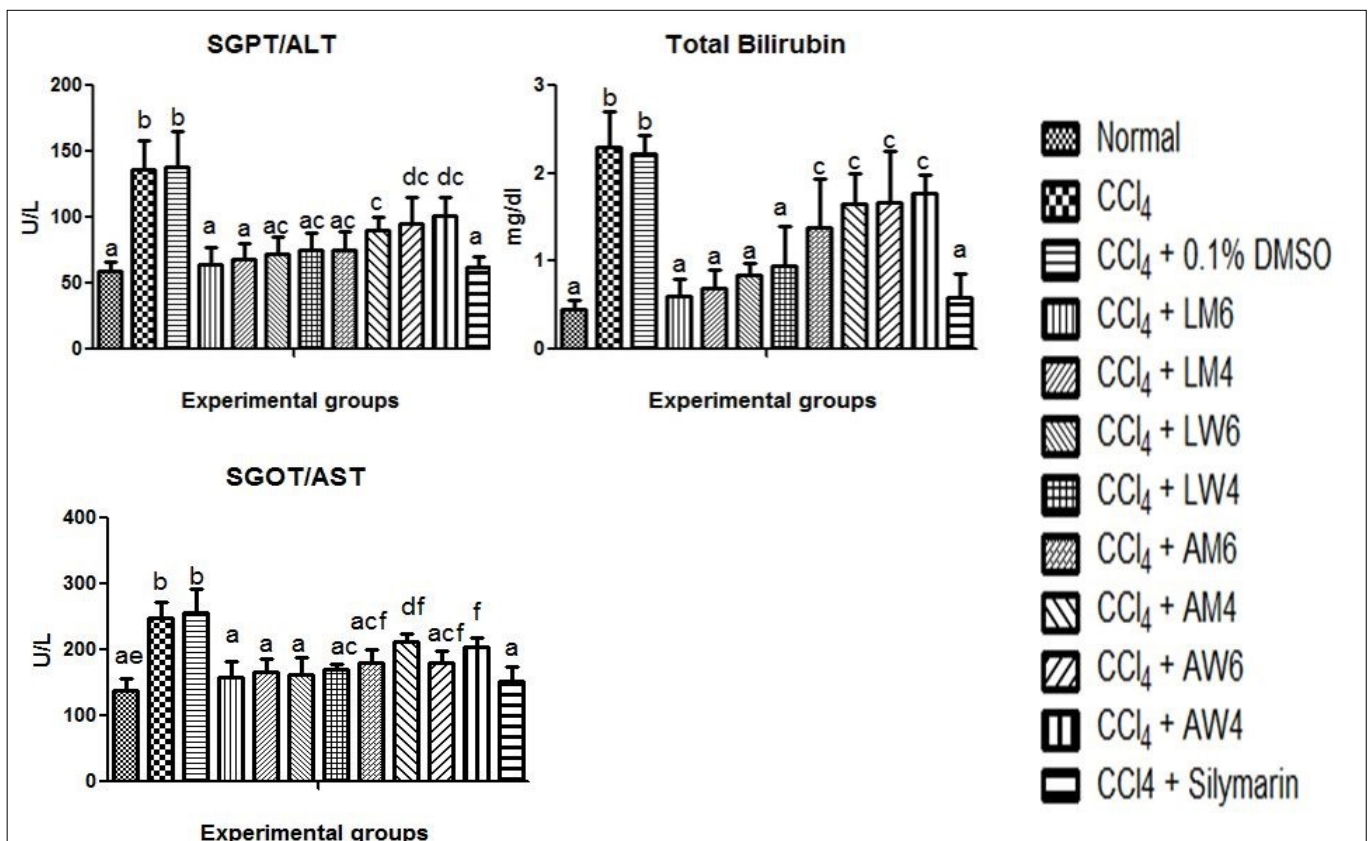
Concentration	LM Percentage protection (%)	LW Percentage protection (%)	AM Percentage protection (%)	AW Percentage protection (%)	Diclofenac sodium 5mg/ml Percentage protection (%)
200 mg/ml	19.54 ± 6.66	18.95 ± 5.56	14.38 ± 4.56	8.84 ± 2.52	
400 mg/ml	31.19 ± 6.09	28.24 ± 3.37	18.04 ± 3.89	18.28 ± 3.10	
600 mg/ml	41.99 ± 3.32	34.29 ± 9.50	19.73 ± 2.35	13.98 ± 3.84	37.54 ± 6.06
800 mg/ml	30.36 ± 2.90	29.39 ± 1.63	19.72 ± 6.93	11.92 ± 3.15	

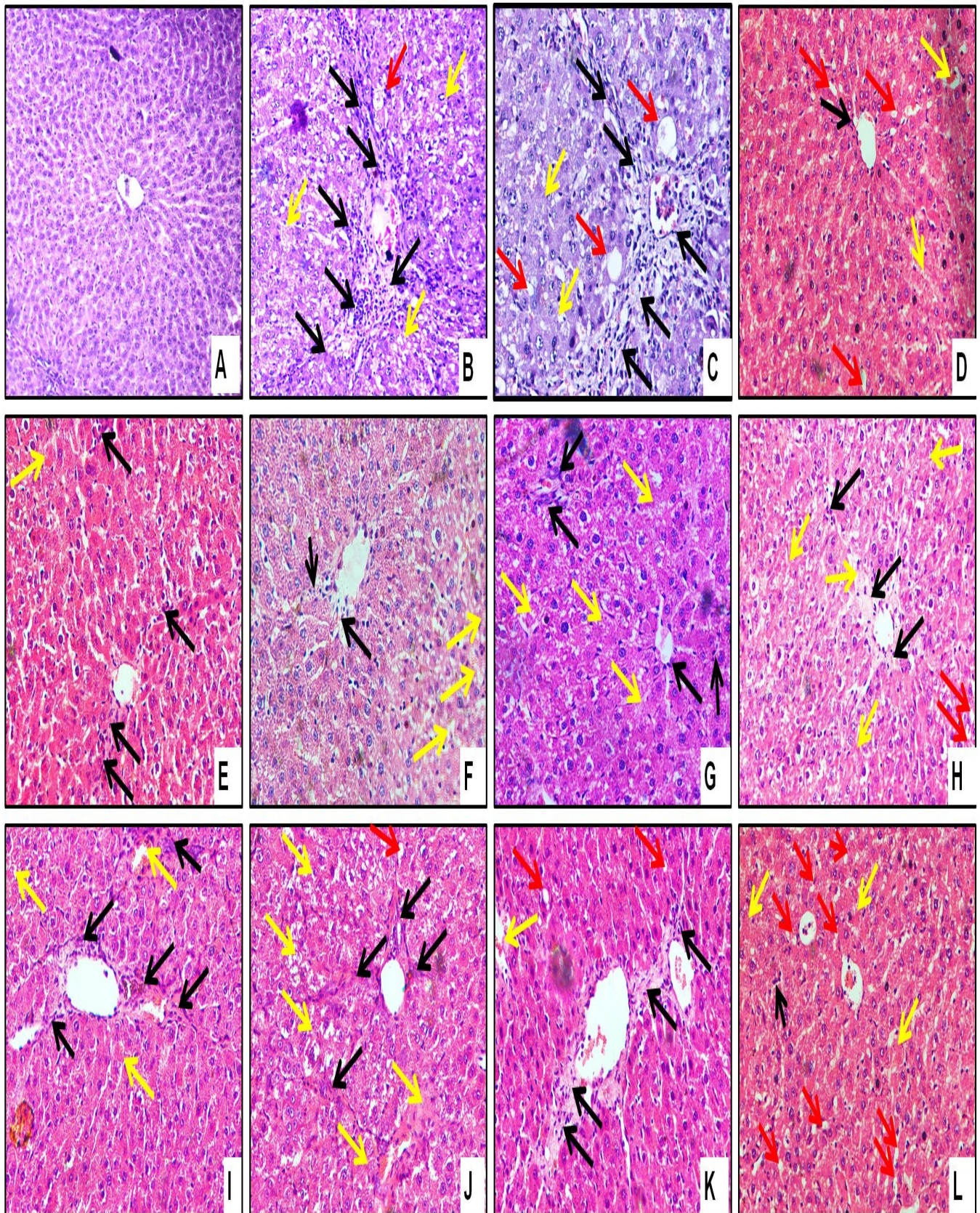
**Table 3.** Body weight, liver weight and liver index of the experimental animals

Animal group	Number of animals (n)	Body weight (g)	Liver weight (g)	Liver index
Control	8	339.13 ± 17.75	10.70 ± 0.82	3.17 ± 0.32
CCl <sub>4</sub>	6	207 ± 22.37 <sup>a,b*#</sup>	14.68 ± 1.85 <sup>b*#</sup>	7.10 ± 0.61 <sup>e*#</sup>
CCl <sub>4</sub> + 0.1% DMSO	6	215.17 ± 24.58 <sup>a*#</sup>	14.89 ± 1.44 <sup>b*#</sup>	6.97 ± 0.72 <sup>e*#</sup>
LM 600 mg/kg + CCl <sub>4</sub>	8	304.71 ± 23.89 <sup>c*</sup>	11.21 ± 0.64 <sup>a</sup>	3.72 ± 0.38 <sup>a</sup>
LM 400 mg/kg + CCl <sub>4</sub>	8	297.75 ± 21.29 <sup>c*</sup>	11.64 ± 1.19 <sup>a</sup>	3.91 ± 0.39 <sup>a</sup>
LW 600 mg/kg + CCl <sub>4</sub>	8	274.13 ± 18.57 <sup>e,f*#</sup>	11.69 ± 1.00 <sup>a</sup>	4.26 ± 0.22 <sup>a,b*</sup>
LW 400 mg/kg + CCl <sub>4</sub>	8	261.63 ± 9.44 <sup>e*#</sup>	12.12 ± 1.06 <sup>a</sup>	4.63 ± 0.39 <sup>a,b,c,*#</sup>
AM 600 mg/kg + CCl <sub>4</sub>	8	239.38 ± 16.26 <sup>a,b,e*#</sup>	11.99 ± 1.42 <sup>a</sup>	5.05 ± 0.84 <sup>b,*#</sup>
AM 400 mg/kg + CCl <sub>4</sub>	8	240.75 ± 20.95 <sup>a,b,e*#</sup>	13.04 ± 0.83 <sup>a*#</sup>	5.47 ± 0.78 <sup>b,c,*#</sup>
AW 600 mg/kg + CCl <sub>4</sub>	8	228.87 ± 18.77 <sup>a*#</sup>	12.33 ± 1.36 <sup>a</sup>	5.44 ± 0.83 <sup>b,c,*#</sup>
AW 400 mg/kg + CCl <sub>4</sub>	7	230.86 ± 29.46 <sup>a*#</sup>	13.13 ± 1.92 <sup>a*#</sup>	5.79 ± 1.31 <sup>b,c,d,*#</sup>
Silymarin 100 mg/kg + CCl <sub>4</sub>	8	313.38 ± 7.41 <sup>*</sup>	10.96 ± 1.15	3.50 ± 0.39

Note: \* represents a significant difference between normal control vs. other groups.

# represents a significant difference between the silymarin standard drug groups vs. other groups. Columns with different superscript letters a, b, c, d and e indicate a significant difference between various treatments ( $p < 0.05$ ). LM (*Lagenandra toxicaria* methanol extract), LW (*Lagenandra toxicaria* water extract), AM (*Ariopsis peltata* methanol extract), AW (*Ariopsis peltata* water extract).

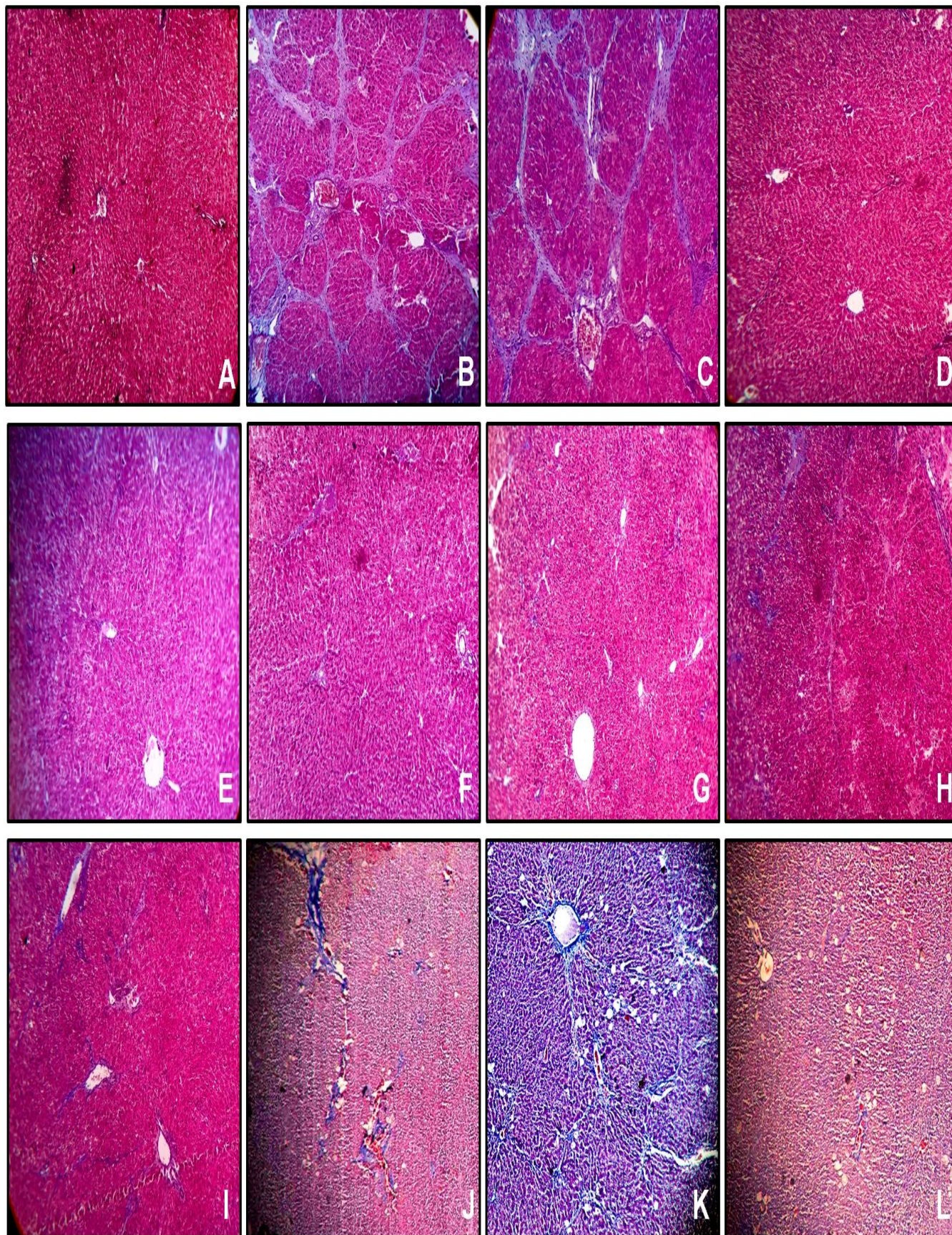
**Fig. 2.** The serum concentration of ALT, AST and TBL in experimental groups.



**Fig. 3a.** Morphology and architecture of the liver examined by H&E stain

cyte disorganization and sinusoidal architectural changes confirming the successful induction of liver fibrosis. The pathological effects of  $\text{CCl}_4$  treatment were seen to be ameliorated in both the plant extract treated groups. The 600 mg/kg *L. toxicaria* methanol extract showed a significant reduction of the liver necrosis and inflammation among all the extracts. Histological scoring of extract treated groups indicates a significant reduction in severity

of inflammation, fatty metamorphosis and necrosis (Fig. 4). Further, the Massonson trichrome (Fig. 3b) shows severe fibrosis in the positive control group. The collagen deposition score (Fig. 4) was significantly reduced in the extract-treated groups. *Lagenandra toxicaria* methanol and water extract treated groups showed very low severity scoring comparable to the standard drug-treated group.



**Fig. 3b.** Collagen deposition in the liver stained with Masson's trichrome stain.

#### Liver antioxidant enzyme and oxidative stress marker

The liver homogenate of the positive control group showed decreased catalase activity and a higher MDA levels. In contrast, the plant extract treated groups showed significantly lower levels of MDA and significantly increased levels of catalase activity. The 600 mg/kg metha-

nol extract of *L. toxicaria* showed results comparable to the standard drug (Table 4).

#### GC-MS analysis

The chromatogram revealed the presence of 21 compounds. The retention time of these compounds are represented in Table 5 and Fig. 5. The compounds were

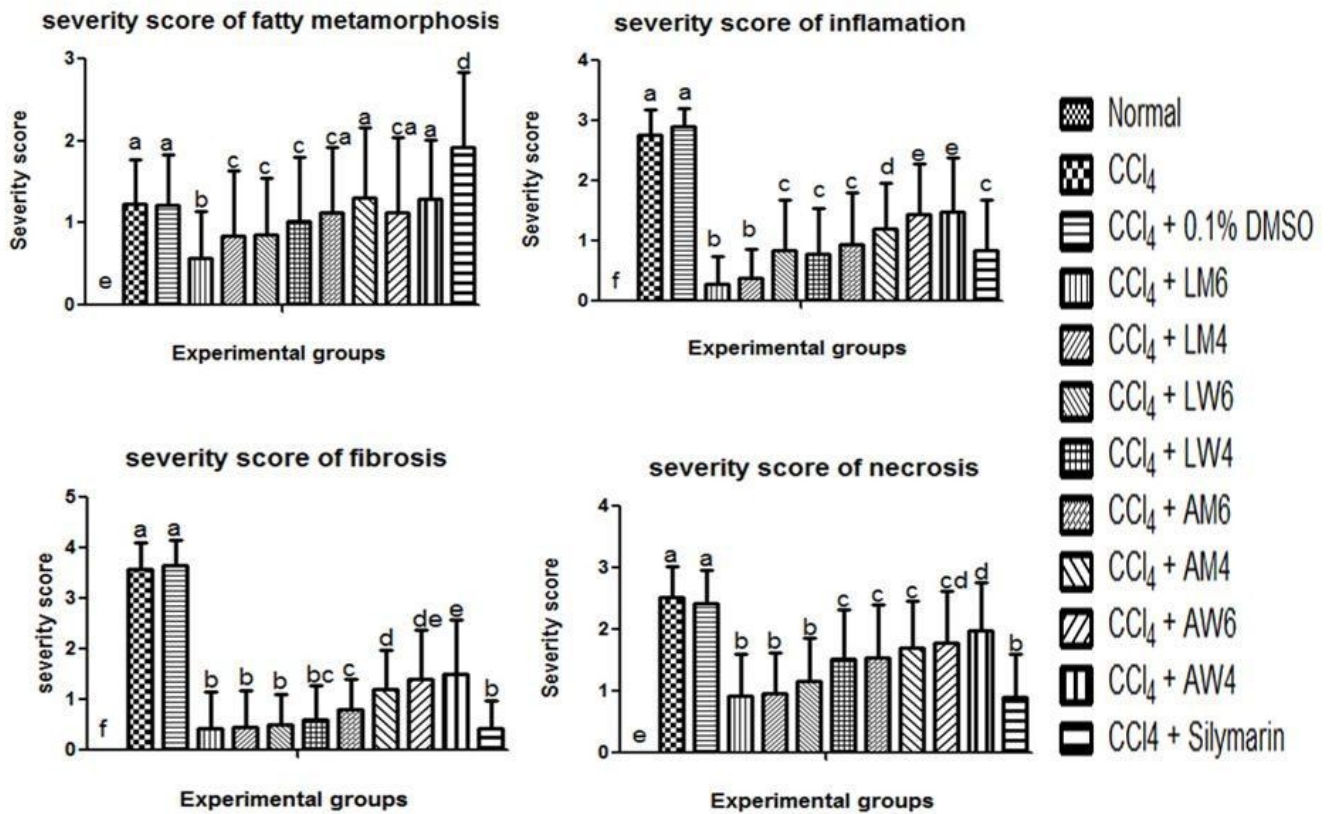


Fig. 4. Severity scoring of fatty metamorphosis, inflammation, fibrosis and necrosis in the extract-treated and untreated groups.

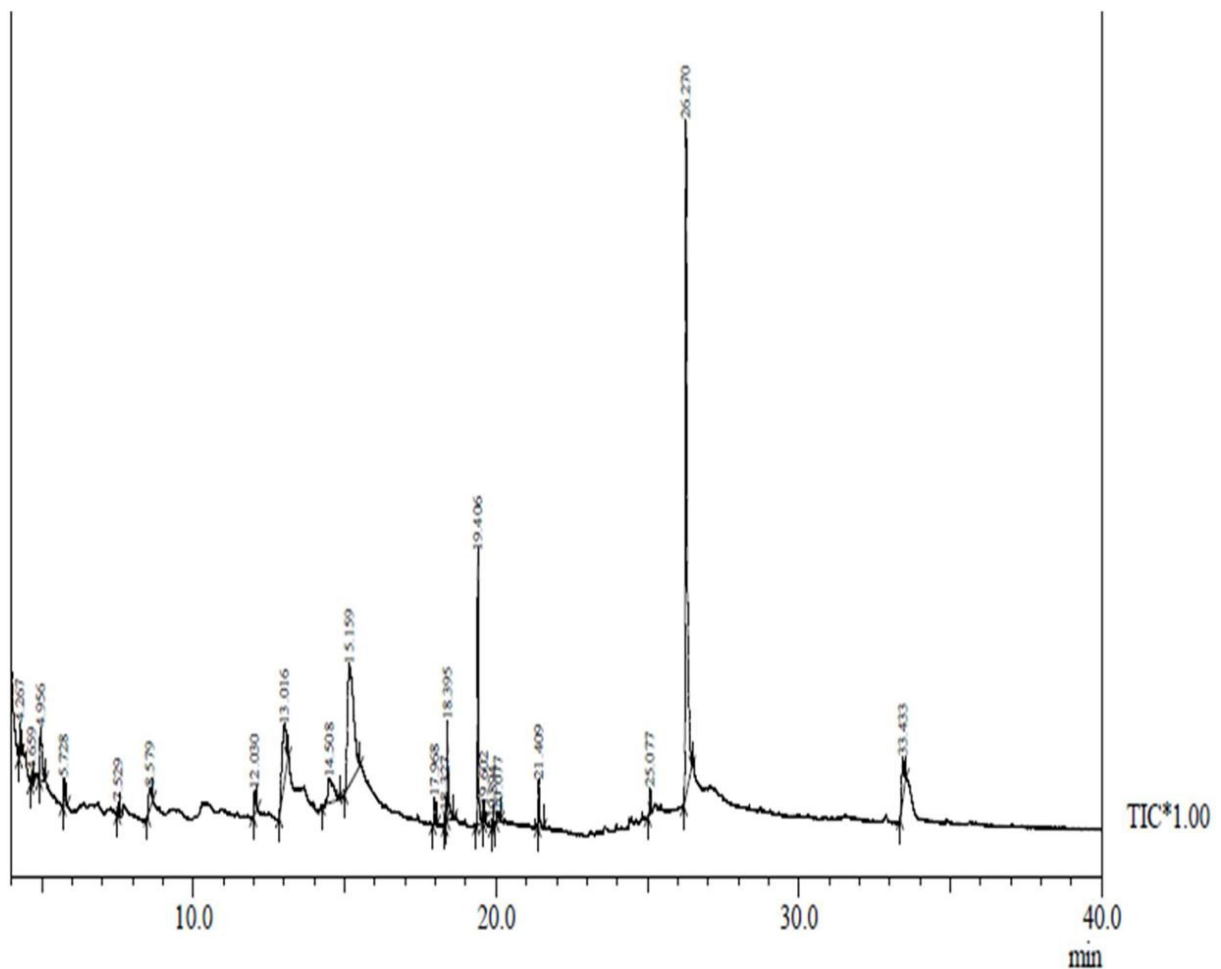


Fig. 5. GC-MS chromatogram of the *Lagenandra toxicaria* methanol extract.

identified by comparing their peak retention time, % peak area and mass spectral fragmentation patterns to those of

the Willy and NIST libraries' recognised compounds. The chromatogram showed a higher amount of 9-



**Table 4.** Lipid peroxidation and catalase activity of the experimental group

Animal group	Lipid peroxidation	Catalase activity
	MDA nmol/mg protein	μmol of H <sub>2</sub> O <sub>2</sub> consumed/min/mg protein
Control	0.71 ± 0.11 a	293.01 ± 14.89 <sup>a</sup>
CCl <sub>4</sub>	2.40 ± 0.62 <sup>b</sup>	194.63 ± 15.64 <sup>c,d,f</sup>
CCl <sub>4</sub> + 0.1% DMSO	2.46 ± 0.55 <sup>b</sup>	196.77 ± 10.15 <sup>c,d,f</sup>
LM 600 mg/kg + CCl <sub>4</sub>	0.72 ± 0.10 <sup>a</sup>	289.27 ± 17.20 <sup>a</sup>
LM 400 mg/kg + CCl <sub>4</sub>	1.00 ± 0.07 <sup>a</sup>	274.16 ± 22.76 <sup>a,b</sup>
LW 600 mg/kg + CCl <sub>4</sub>	1.14 ± 0.36 <sup>a</sup>	263.42 ± 21.20 <sup>b</sup>
LW 400 mg/kg + CCl <sub>4</sub>	1.27 ± 0.29 <sup>a</sup>	255.57 ± 10.70 <sup>b</sup>
AM 600 mg/kg + CCl <sub>4</sub>	1.37 ± 0.13 <sup>a</sup>	232.34 ± 16.69 <sup>c,d,e</sup>
AM 400 mg/kg + CCl <sub>4</sub>	1.49 ± 0.08 <sup>a</sup>	218.56 ± 17.20 <sup>c,d</sup>
AW 600 mg/kg + CCl <sub>4</sub>	1.46 ± 0.41 <sup>a</sup>	218.64 ± 12.62 <sup>c,d</sup>
AW 400 mg/kg + CCl <sub>4</sub>	1.51 ± 0.40 <sup>a</sup>	210.66 ± 2.39 <sup>c,d</sup>
Silymarin 100 mg/kg + CCl <sub>4</sub>	0.88 ± 1.54 <sup>a</sup>	290.77 ± 20.38 <sup>a</sup>

octadecenamamide with a peak area of 36.53 %.

## Discussion

Liver fibrosis is stimulated by oxidative stress, inflammation and cellular apoptosis from viral infection or other toxicants (5, 22). Inflammatory cells have been linked to the induction of neutrophils and lymphocytes, which in turn promote fibrosis (23). The oxidative stress activates

the NF-κB which stimulates the hepatic stellate cells. It also induces production of cytokines like TNF-α, TGF-β, IL-1β, IL-6, Cox-2 that promotes inflammation and fibrosis. NF-κB regulates the inflammatory pathway genes (24, 25). It was opined that the antioxidant and anti-inflammatory compounds play a major role in the treatment of liver fibrosis (5). Here, both the plant extracts showed good antioxidant activity. In the DPPH and FRAP assays, *L. toxicaria* methanol extract showed higher antioxidant potency than *A. peltata*.

The stabilization of the lysosomal membrane is critical for limiting the inflammatory response. Erythrocyte membrane is similar to the lysosomal membrane (16, 26). The stabilization of the erythrocyte membrane by HRBC method confirms the anti-inflammatory activity of the extracts. The *In-vitro* anti-inflammatory study clearly showed that the percentage of protection increased in a concentration dependent manner up to 600 mg/ml in all the extracts and the protection decreased at 800 mg/ml concentration. Among the other extracts, the *L. toxicaria* methanol extract showed higher anti-inflammatory activity at 600 mg/ml.

The CCl<sub>4</sub> induced liver fibrosis model is widely used to study different aspects of liver fibrosis and healing (27). Repeated administration of CCl<sub>4</sub> induces lipid peroxidation and the injured hepatocytes release the cellular components. These induce the inflammatory response leading to fibrosis (28, 29). At present, liver transplantation is the

**Table 5.** Identification of the bioactive components of *Lagenandra toxicaria* rhizome methanol extract.

Sl.no	R.Time	Area %	Mol. formula	Mol. weight	Compound name	Properties of the compound
1	4.267	0.75	C <sub>5</sub> H <sub>8</sub> O <sub>2</sub>	96	4-Cyclopentene-1,2-dione	Antifungal
2	4.659	0.38	C <sub>4</sub> H <sub>6</sub> O <sub>2</sub>	86	2(3H)-Furanone	immunosuppressive
3	4.956	3.39	C <sub>5</sub> H <sub>6</sub> O <sub>2</sub>	98	2-Cyclopenten-1-one, 2-hydroxy-	
4	5.728	1.22	C <sub>6</sub> H <sub>8</sub> O <sub>4</sub>	144	2,4-Dihydroxy-2,5-dimethyl-3(2H)-furan-3-one	Flavouring agent
5	7.529	0.24	C <sub>11</sub> H <sub>24</sub>	156	Undecane	Anti-allergic and anti-inflammatory
6	8.579	1.92	C <sub>6</sub> H <sub>8</sub> O <sub>4</sub>	144	4H-Pyran-4-one, 2,3-dihydro-3,5-dihydroxy-6-methyl-	
7	12.030	1.18	C <sub>12</sub> H <sub>13</sub> N <sub>7</sub>	255	3H-Indole-3-carbaldehyde (4-amino-5-methyl-4h-1,2,4-triazol-3-yl)hydrazone	
8	13.016	7.99	C <sub>5</sub> H <sub>10</sub> O	86	Cyclopentanol	
9	14.508	4.13	C <sub>7</sub> H <sub>14</sub> O <sub>6</sub>	194	alpha.-D-Fructofuranoside, methyl	
10	15.159	22.83	C <sub>7</sub> H <sub>14</sub> O <sub>6</sub>	194	alpha.-Methyl-l-sorboside	
11	17.968	0.67	C <sub>17</sub> H <sub>34</sub> O <sub>2</sub>	270	Hexadecanoic acid, methyl ester	
12	18.327	0.30	C <sub>16</sub> H <sub>22</sub> O <sub>4</sub>	278	Dibutyl phthalate	Antimicrobial
13	18.395	4.34	C <sub>16</sub> H <sub>32</sub> O <sub>2</sub>	256	n-Hexadecanoic acid	Anti-inflammatory
14	19.406	7.46	C <sub>18</sub> H <sub>32</sub> O <sub>2</sub>	280	13-Hexyloxacyclotridec-10-en-2-one	
15	19.602	0.33	C <sub>19</sub> H <sub>34</sub> O <sub>2</sub>	294	9,12-Octadecadienoic acid, methyl ester	
16	19.894	0.17	C <sub>21</sub> H <sub>42</sub> O <sub>2</sub>	326	Eicosanoic acid, methyl ester	
17	20.077	0.64	C <sub>18</sub> H <sub>36</sub> O	268	9-Octadecen-1-ol,	
18	21.409	1.71	C <sub>19</sub> H <sub>36</sub> O <sub>3</sub>	312	9-Octadecenoic acid, 12-hydroxy-, methyl ester,	
19	25.077	0.86	C <sub>12</sub> H <sub>23</sub> NO <sub>2</sub>	213	3-Cyclopentylpropionic acid, 2-dimethylaminoethyl ester	
20	26.270	36.53	C <sub>18</sub> H <sub>35</sub> NO	281	9-Octadecenamamide	Anti-inflammatory, Sedative
21	33.433	2.96	C <sub>29</sub> H <sub>48</sub> O	412	Stigmasta-5,20(22)-dien-3-ol-	anti-inflammatory, anti-hypercholesterolemic

most effective strategy to address liver fibrosis. It has many limitations, like the shortage of organ donors, immunological rejection, surgical complications and its high cost (5). In recent years, various herbal remedies have been demonstrated to possess anti-fibrotic activities and is being used to treat fibrosis (7). According to one study (30) bile duct ligation induced hepatic fibrosis in rat model was treated with artemepavine showed antifibrotic activity through the anti NF- $\kappa$ B activation pathway. Salvianolic acid B is a water-soluble, bioactive compound isolated from *Salvia miltiorrhiza*. It also significantly lowers the NF- $\kappa$ B, and I $\kappa$ B $\alpha$  levels and reduces the CCl<sub>4</sub> induced liver fibrosis (31). The biochemical analysis and histological studies showed that the CCl<sub>4</sub> induced damages were successfully reversed by the plant extracts. The *L. toxicaria* methanol extract treated rats showed higher recovery than the other extracts. The severity scoring of the pathological changes have significantly decreased after the treatment.

The innate antioxidant enzyme defence system is a natural guard of organs against oxidative stress. The enzyme catalase protects the cells by breaking the toxic hydrogen peroxide into water and oxygen (32). CCl<sub>4</sub> inhibits the natural antioxidants in the liver tissue and increases the MDA (33). Our study showed that both the plant extracts co-treatment in CCl<sub>4</sub> treated animals showed increased levels of antioxidant enzymes. Also, a reduction in the lipid peroxidation was seen in all the extract treated groups. The 600 mg/kg methanol extract of *L. toxicaria* showed very low lipid peroxidation compared to the other extract treated groups (Table 4).

The GC-MS analysis of the *L. toxicaria* methanol extract showed some major compounds like Cyclopentanol, Alpha-methyl-sorbose, Palmitic acid, 13 - Hexyloxacyclotridec - 10 - en - 2 - one, 9-octadecenamide and stigmasterol. Studies have shown that octadecenamide, palmitic acid and Stigmasta-5, 20 (22)-dien-3-ol- have anti-inflammatory activity (34). The GC-MS findings indicate a higher percentage of 9-octadecenamide. The 9-octadecenamide which is an oleamide was reported to have antioxidant and anti-inflammatory activity (35, 36). The therapeutic effects of oleamide are being widely studied. Oleamide extracted from the green algae *Codium fragile* reduces the production of IL-1, IL-6 and translocation of NF- $\kappa$ B. The effects of oleamide in the carrageenan-induced rat inflammatory model were comparable to the non-steroidal, anti-inflammatory medication, diclofenac (37). A decreased histamine and -hexosaminidase secretion and reduced interleukin-4 (IL-4) and TNF- $\alpha$  production were seen in the oleamide derived from *Arctium lappa* extract which is proof of its anti-allergic potential (38). Oleamides are also linked to certain neuroprotective properties including anti-inflammatory responses in a rat model of Alzheimer's disease (39). Several liver illnesses, such as hepatitis, liver fibrosis, cirrhosis and hepatocellular carcinoma, are linked to the NF- $\kappa$ B pathway. As a result, the NF- $\kappa$ B pathway is a possible target for hepatoprotective drug development (40). Studies have shown that oleamide has a very good affinity towards the NF- $\kappa$ B and would inhibit the activation of inflammatory pathways (37, 41). Therefore, the 9-octadecenamide offered anti-inflammatory and antioxi-

dant properties of *L. toxicaria* methanol extract could be the mechanism that leads to extracts' anti-fibrotic action against CCl<sub>4</sub> induced liver fibrosis.

## Conclusion

Good amounts of bioactive compounds, including phenols and flavonoids were present in the water and methanol extracts of *Lagenandra toxicaria* and *Ariopsis peltata*. The methanol extract of *L. toxicaria* exhibits a greater antioxidant capacity than the other extracts. This can be attributed to the higher concentration of phenols and flavonoids. Both the plant extracts showed resistance to CCl<sub>4</sub>-induced liver fibrosis. The methanol extract of *L. toxicaria* 600 mg/kg showed higher amelioration of CCl<sub>4</sub> induced collagen accumulation and inflammation. The GC-MS analysis of *L. toxicaria* methanol extract revealed the presence of bioactive compounds such as octadecenamide, palmitic acid and stigma steroids, which have anti-inflammatory and antifibrotic activities. Therefore, the *L. toxicaria* plant extract can be effectively used to treat liver fibrosis

## Acknowledgements

We are grateful to the Director of the DST PURSE and USIC Mangalore University for providing the necessary facilities to carry out the research. The authors are also thankful to the Directorate of Minorities, Karnataka for providing the necessary financial support (DOM/FELLOWSHIP/CR-2/2017-18).

## Authors contributions

AB carried out the experiments, analysis and preparation of the manuscript. KG assisted in the planning, investigation of the experiment and final evaluation of the manuscript. PS guided the animal experiments. All authors approved the final manuscript.

## Compliance with ethical standards

**Conflict of interest:** The authors declare that they have no conflicts of interest.

**Ethical issues:** The animal experiments were approved by the animal ethical committee of Nitte institute, deemed to be University, the protocol number (NGSMIPS/IAEC/MARCH-2019/124).

## References

1. John LA, Kannappan N, Manojkumar P. Evaluation of Hepatoprotective activity in methanolic extract of Aerial parts of *Hibiscus surattensis*. Res J Pharm Technol. 2020;13(10):4635-40. <http://dx.doi.org/10.5958/0974-360X.2020.00816.1>
2. Asrani SK, Devarbhavi H, Eaton J, Kamath PS. Burden of liver diseases in the world. J Hepatol. 2019;70(1):151-71. <https://doi.org/10.1016/j.jhep.2018.09.014>
3. Guo Y, Liang X, Meng M, Chen H, Wei X, Li M, et al. Hepatoprotective effects of Yulansan flavone against carbon tetrachloride (CCl<sub>4</sub>)-induced hepatic fibrosis in rats. Phytomedicine. 2017;33:28-35. <https://doi.org/10.1016/j.phymed.2017.07.005>

4. Latief U, Ahmad R. Herbal remedies for liver fibrosis: A review on the mode of action of fifty herbs. *J Tradit Complement Med.* 2018;8(3):352–60. <https://doi.org/10.1016/j.jtcme.2017.07.002>
5. Lam P, Cheung F, Tan HY, Wang N, Yuen MF, Feng Y. Hepatoprotective effects of Chinese medicinal herbs: a focus on anti-inflammatory and anti-oxidative activities. *Int J Mol Sci.* 2016;17(4):465. <https://doi.org/10.3390/ijms17040465>
6. Zhang A, Sun H, Wang X. Recent advances in natural products from plants for treatment of liver diseases. *Eur J Med Chem.* 2013;63:570–7. <https://doi.org/10.1016/j.ejmech.2012.12.062>
7. El-Tantawy WH, Temraz A. Anti-fibrotic activity of natural products, herbal extracts and nutritional components for prevention of liver fibrosis: review. *Arch Physiol Biochem.* 2019;0(0):1–12. <https://doi.org/10.1080/13813455.2019.1684952>
8. Tuse TA, Harle UN, Bore VV. Hepatoprotective activity of *Colocasia antiquorum* against experimentally induced liver injury in rats. *Malaysian J Pharma Sci.* 2009;7(2):99–112
9. Sharstry RA, Biradar SM, Mahadevan KM, Habbu PV. Isolation and characterization of secondary metabolite from *Amorphophallus paeoniifolius* for hepatoprotective activity. *Res J Pharm Biol Chem Sci.* 2010;1(4):429–37
10. Rahman MA, Solaiman M, Haque ME, Das AK. Analgesic and anti-inflammatory activities of *Alocasia indica* (Roxb.) Schott. *Orient Pharm Exp Med.* 2011;11(3):143–6. <https://doi.org/10.1007/s13596-011-0027-1>
11. Annie Sulochana Selvakumari P. Pharmacognostical standardisation of *Lagenandra toxicaria* Dalz. *Malays J Sci.* 2014;33(2):163–75. <https://doi.org/10.22452/mjs.vol33no2.5>
12. Bhat S, Mulgund GS, Hegde S, Hegde HV. Pharmacognostic evaluation and phytochemical analysis of leaf and tuber of *Ariopsis peltata* Nimmo. *J Pharmacogn Phytochem.* 2019;8(1):1608–15.
13. Devi HP, Mazumder PB. Methanolic extract of *Curcuma caesia* Roxb. prevents the toxicity caused by cyclophosphamide to bone marrow cells, liver and kidney of mice. *Pharmacogn Res.* 2016;8(1):43. <https://doi.org/10.4103/2F0974-8490.171106>
14. Khanal S, Shakya N, Thapa K, Pant DR. Phytochemical investigation of crude methanol extracts of different species of *Swertia* from Nepal. *BMC Res Notes.* 2015;8(1):1–9. <https://doi.org/10.1186/s13104-015-1753-0>
15. Bhalodia NR, Nariya PB, Acharya RN, Shukla VJ. In vitro antioxidant activity of hydro alcoholic extract from the fruit pulp of *Cassia fistula* Linn. *Ayu.* 2013;34(2):209–14. <https://doi.org/10.4103/0974-8520.119684>
16. Saleem TM, Azeem AK, Dilip C, Sankar C, Prasanth NV, Duraisami R. Anti-inflammatory activity of the leaf extracts of *Gendarussa vulgaris* Nees. *Asian Pac J Trop Biomed.* 2011;1(2):147–9. [https://doi.org/10.1016/S2221-1691\(11\)60014-2](https://doi.org/10.1016/S2221-1691(11)60014-2)
17. Vogel HG. Drug discovery and evaluation: pharmacological assays. Springer Science & Business Media; 2002. <https://doi.org/10.1007/978-3-540-70995-4>
18. Wang R, Wang J, Song F, Li S, Yuan Y. Tanshinol ameliorates CCl<sub>4</sub>-induced liver fibrosis in rats through the regulation of Nrf2/HO-1 and NF- $\kappa$ B/I $\kappa$ B $\alpha$  signaling pathway. *Drug Des Devel Ther.* 2018;12:1281–92. <https://doi.org/10.2147/DDDT.S159546>
19. Jayakumar T, Ramesh E, Geraldine P. Antioxidant activity of the oyster mushroom, *Pleurotus ostreatus*, on CCl<sub>4</sub>-induced liver injury in rats. *Food Chem Toxicol.* 2006 Dec 1;44(12):1989–96. <https://doi.org/10.1016/j.fct.2006.06.025>
20. Gui SY, Wei W, Wang H, Wu L, Sun WY, Chen W bi, *et al.* Effects and mechanisms of crude astragalosides fraction on liver fibrosis in rats. *J Ethnopharmacol.* 2006;103(2):154–9. <https://doi.org/10.1016/j.jep.2005.07.025>
21. Sinha AK. Colorimetric assay of catalase. *Anal Biochem.* 1972;47(2):389–94. [https://doi.org/10.1016/0003-2697\(72\)90132-7](https://doi.org/10.1016/0003-2697(72)90132-7)
22. Hamza AA. Ameliorative effects of *Moringa oleifera* Lam seed extract on liver fibrosis in rats. *Food Chem Toxicol.* 2010;48(1):345–55. <https://doi.org/10.1016/j.fct.2009.10.022>
23. Czaja AJ. Hepatic inflammation and progressive liver fibrosis in chronic liver disease. *World J Gastroenterol WJG.* 2014;20(10):2515. <https://doi.org/10.3748/wjg.v20.i10.2515>
24. Heeba GH, Mahmoud ME. Therapeutic potential of morin against liver fibrosis in rats: modulation of oxidative stress, cytokine production and nuclear factor kappa B. *Environ Toxicol Pharmacol.* 2014;37(2):662–71. <https://doi.org/10.1016/j.etap.2014.01.026>
25. Jia R, Li Y, Cao L, Du J, Zheng T, Qian H, *et al.* Antioxidative, anti-inflammatory and hepatoprotective effects of resveratrol on oxidative stress-induced liver damage in tilapia (*Oreochromis niloticus*). *Comp Biochem Physiol Part C Toxicol Pharmacol.* 2019;215:56–66. <https://doi.org/10.1016/j.cbpc.2018.10.002>
26. Anosike CA, Obidoa O, Ezeanyika LU. Membrane stabilization as a mechanism of the anti-inflammatory activity of methanol extract of garden egg (*Solanum aethiopicum*). *DARU J Pharm Sci.* 2012;20(1):1–7. <https://doi.org/10.1186/2008-2231-20-76>
27. Yanguas SC, Cogliati B, Willebrords J, Maes M, Colle I, Van den Bossche B, *et al.* Experimental models of liver fibrosis. *Arch Toxicol.* 2016;90(5):1025–48. <https://doi.org/10.1007/s00204-015-1543-4>
28. Roh JS, Sohn DH. Damage-Associated Molecular Patterns in Inflammatory Diseases. *Immune Netw.* 2018 Aug 1;18(4). <https://doi.org/10.4110/in.2018.18.e27>
29. Dong X, Liu J, Xu Y, Cao H. Role of macrophages in experimental liver injury and repair in mice. *Exp Ther Med.* 2019 Mar 27;17(5):3835. <https://doi.org/10.3892/etm.2019.7450>
30. Weng TC, Shen CC, Chiu YT, Lin YL, Kuo CD, Huang YT. Inhibitory effects of artemepavine against hepatic fibrosis in rats. *J Biomed Sci.* 2009;16(1):1–13. <https://doi.org/10.1186/1423-0127-16-78>
31. Wang R, Yu XY, Guo ZY, Wang YJ, Wu Y, Yuan YF. Inhibitory effects of salvianolic acid B on CCl<sub>4</sub>-induced hepatic fibrosis through regulating NF- $\kappa$ B/I $\kappa$ B $\alpha$  signaling. *J Ethnopharmacol.* 2012;144(3):592–8. <https://doi.org/10.1016/j.jep.2012.09.048>
32. Medina J, Moreno-Otero R. Pathophysiological basis for antioxidant therapy in chronic liver disease. *Drugs.* 2005;65(17):2445–61. <https://doi.org/10.2165/00003495-200565170-00003>
33. Vuda M, D'Souza R, Upadhyaya S, Kumar V, Rao N, Kumar V, *et al.* Hepatoprotective and antioxidant activity of aqueous extract of *Hybanthus enneaspermus* against CCl<sub>4</sub>-induced liver injury in rats. *Exp Toxicol Pathol.* 2012;64(7–8):855–9. <https://doi.org/10.1016/j.etp.2011.03.006>
34. Hoffmann C, Djerir NEH, Danckaert A, Fernandes J, Roux P, Charrueau C, *et al.* Hepatic stellate cell hypertrophy is associated with metabolic liver fibrosis. *Sci Rep.* 2020;10(1):1–13. <https://doi.org/10.1038/s41598-020-60615-0>
35. Chouhan S, Guleria S. Anti-inflammatory Activity of Medicinal Plants: Present Status and Future Perspectives. In: *Botanical Leads for Drug Discovery.* Springer; 2020. p. 67–92. [https://doi.org/10.1007/978-981-15-5917-4\\_4](https://doi.org/10.1007/978-981-15-5917-4_4)
36. Olaoluwa OO, James DA, Adigun OA. Volatile oil analysis of aerial parts of *Boerhavia coccinea* (Mill.). *Nat Prod Res.* 2018;32(8):959–62. <https://doi.org/10.1080/14786419.2017.1366477>
37. Moon SM, Lee SA, Hong JH, Kim JS, Kim DK, Kim CS. Oleamide suppresses inflammatory responses in LPS-induced RAW264. 7 murine macrophages and alleviates paw edema in a carrageenan-induced inflammatory rat model. *Int Immunopharmacol.* 2018;56:179–85. <https://doi.org/10.1016/j.intimp.2018.01.032>
38. Yang WS, Lee SR, Jeong YJ, Park DW, Cho YM, Joo HM, *et al.* Antiallergic activity of ethanol extracts of *Arctium lappa* L. undried roots and its active compound, oleamide, in regulating

- FcεRI-mediated and MAPK signaling in RBL-2H3 cells. *J Agric Food Chem.* 2016;64(18):3564–73. <https://doi.org/10.1021/acs.jafc.6b00425>
39. Ano Y, Ozawa M, Kutsukake T, Sugiyama S, Uchida K, Yoshida A, *et al.* Preventive effects of a fermented dairy product against Alzheimer's disease and identification of a novel oleamide with enhanced microglial phagocytosis and anti-inflammatory activity. *PLoS One.* 2015;10(3):e0118512. <https://doi.org/10.1371/journal.pone.0118512>
40. Seki E, Schwabe RF. Hepatic inflammation and fibrosis: functional links and key pathways. *Hepatology.* 2015;61(3):1066–79. <https://doi.org/10.1002/hep.27332>
41. Oh YT, Lee JY, Lee J, Lee JH, Kim JE, Ha J, *et al.* Oleamide suppresses lipopolysaccharide-induced expression of iNOS and COX-2 through inhibition of NF-κB activation in BV2 murine microglial cells. *Neurosci Lett.* 2010;474(3):148–53. <https://doi.org/10.1016/j.neulet.2010.03.026>

§§§