



RESEARCH ARTICLE

# Portulaca grandiflora phytochemicals as a potential source for wound healing activity: *in vitro* and *in vivo* studies

Hadeel Kareem Mus'hib\*, Thukaa Z. Abdul-Jalil

Department of Pharmacognosy and Medicinal Plants, College of Pharmacy, University of Baghdad, Baghdad, Iraq

\*Email: [Hadeel.Kareem2200m@copharm.uobaghdad.edu.iq](mailto:Hadeel.Kareem2200m@copharm.uobaghdad.edu.iq)

 OPEN ACCESS

## ARTICLE HISTORY

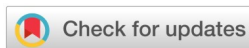Received: 29 June 2024

Accepted: 23 July 2024

Available online

Version 1.0 : 04 August 2024

Version 2.0 : 07 August 2024



## Additional information

**Peer review:** Publisher thanks Sectional Editor and the other anonymous reviewers for their contribution to the peer review of this work.

**Reprints & permissions information** is available at [https://horizonepublishing.com/journals/index.php/PST/open\\_access\\_policy](https://horizonepublishing.com/journals/index.php/PST/open_access_policy)

**Publisher's Note:** Horizon e-Publishing Group remains neutral with regard to jurisdictional claims in published maps and institutional affiliations.

**Indexing:** Plant Science Today, published by Horizon e-Publishing Group, is covered by Scopus, Web of Science, BIOSIS Previews, Clarivate Analytics, NAAS, UGC Care, etc See [https://horizonepublishing.com/journals/index.php/PST/indexing\\_abstracting](https://horizonepublishing.com/journals/index.php/PST/indexing_abstracting)

**Copyright:** © The Author(s). This is an open-access article distributed under the terms of the Creative Commons Attribution License, which permits unrestricted use, distribution and reproduction in any medium, provided the original author and source are credited (<https://creativecommons.org/licenses/by/4.0/>)

## CITE THIS ARTICLE

Mus'hib HK, Abdul-Jalil TZ. Portulaca grandiflora phytochemicals as a potential source for wound healing activity: *in vitro* and *in vivo* studies. Plant Science Today. 2024; 11 (3): 504-511. <https://doi.org/10.14719/pst.4209>

## Abstract

The management of chronic wounds presents considerable challenges and has a substantial influence on the quality of life among afflicted persons and their families. The discovery of naturally produced bioactive chemicals having good effects on the regeneration of tissue has been driven by the need for safe, effective, and cost-effective wound healing therapies. *Portulaca grandiflora* is an annual succulent that comes under the family of Portulacaceae. The purpose of this study was to evaluate the phytochemicals of n-hexane extracts and their effects on *in vitro* and *in vivo* wound healing models. *In vitro* study, Wound Scratch Assay shows that n-hexane extract of 100 ug/ml concentration significantly promotes wound healing through increased cell migration and wound closure compared to MEBO ointment-treated groups and negative control groups. The *in vivo* study shows that the formula of the extract ointment promotes wound healing without any complication and the percentage of wound surface area reduction was ( $5.39 \pm 0.391$ ) better than MEBO-treated groups ( $10.06 \pm 0.536$ ), and negative control groups ( $14.04 \pm 0.304$ ) through its ability to stimulate epidermal closure, re-epithelization, and granulation that appears in histological examination. As a result, Iraqi *Portulaca grandiflora* can be considered a potential resource of chemical substances, especially terpenoids, and steroids, which are helpful in healing wounds.

## Keywords

*in vitro*; *in vivo*; n-hexane fraction; *Portulaca grandiflora*; Wound Scratch Assay

## Introduction

The word "wound" is used to describe the modification of living tissues resulting from a physical force that causes the skin to be lacerated, since the skin is particularly susceptible to tissue injury. Wound healing is the innate and typical response of the body to harm. The process is intricate and constantly changing, helping damaged tissues to regenerate rapidly and regain their original function (1). The healing process is classically divided into four highly interrelated and overlapping phases: coagulation (hemostasis), inflammation and proliferation (granulation), and remodeling (maturation) (2). The use of medicinal plants has arisen as a means to enhance well-being and mitigate illnesses, owing to their reduced toxicity and affordability. The existing body of literature indicates that around 33% of traditional medicines have the potential to be used in the treatment of wounds and skin problems, in contrast to a mere 1-3% of synthesized contemporary pharmaceuticals (3-5). *Portulaca grandiflora* is an annual succulent that comes under the family of Portulacaceae and is an extremely

tough plant that thrives in adverse conditions (6). Several different phenotypes were seen, with petal colors varying from white to deep yellow, orange, red, magenta, and pale yellow (7). It is a small herbaceous annual plant; common names include Moss Rose, Rose Moss, and Sun plant. According to oriental traditional medicine, *P. grandiflora* relieves sore throat, skin rash, and inflammation (8) as a lotion for snake and insect bites, burns, scalds, and eczema (9,10). The pharmacological activity of *P. grandiflora* extracts is antioxidant and antifungal (11). It possesses broad-spectrum antimicrobial activities (12), anticancer activity, (13) Antidiabetic activity (14), and anti-Parkinson's activity (15). Numerous *in vitro* and *in vivo* models have been advanced to investigate the process of wound healing. These models play a vital role in facilitating scientists' ability to conduct translational research, particularly in the context of clinical investigations, to enhance wound care and treatment (16). The present investigation illustrates the phytochemicals that are present in the n-hexane extract of the Iraqi *P. grandiflora* plant and defines our efforts to assess the *in vitro/in vivo* wound healing potential.

## Materials and Methods

### Collection and Authentication of Plant Materials

Between June and July 2023, the cultivated Iraqi *P. grandiflora* L plant, whole fresh plants, were collected from Zayona plant nurseries in Baghdad, Iraq. The freshly grown plants were recognized, validated, and certified by Dr. Israa Abdulrazaq, affiliated with the College of Biology at the University of Baghdad. The plants underwent a series of procedures, including cleaning, drying in a shaded area at ambient temperature, crushing using an electrical method, and weighing before extraction.

### Extraction of plant material: Soxhlet Apparatus (Hot method)

Soxhlet Apparatus (hot extraction technique) used for various phytoconstituents extraction. A thimble containing 100 grams of finely powdered *P. grandiflora* was prepared and thereafter subjected to extraction using 800 milliliters of n-hexane at a temperature of 50°C. Subsequently, the extract underwent filtration and concentration using a rotary evaporator (17). Fig.1 summarizes the present study including plant extraction, *in vivo*, and *in vitro* wound healing studies of the *P. Grandiflora* plant.

### Qualitative phytochemical analysis

**Salkowski analysis:** A mixture was prepared by combining 3 ml of concentrated sulfuric acid with 2 ml of chloroform, along with 0.5 mg of plant hexane extract. Oxidation caused a rusty-brown color to form.

**Liebermann-Burchard evaluation procedure:** Dissolve 0.5 mg of the plant's hexane extract in 5 ml of chloroform, then dehydrate the chloroform layer using Sodium sulfate (anhydrous). Subsequently, 2 drops of strong sulfuric acid and 10 drops of pure acetic anhydride were added to the prepared solution. Oxidation of the material causes a change in color to bluish-green, indicating the existence of the steroidal nucleus (18).

### Assessment of the Wound-Healing Activity

#### *In vitro* Wound Scratch Assay

Following detachment of the rat embryo fibroblast (REF) cells from the flask surface through gentle tapping, 20 ml of (RPMI-1640) culture medium was added with 10% fetal bovine serum. (19). The cellular solution was thoroughly homogenized and then transferred at a density of  $2 \times 10^5$  cells per well to a 24-well plate via an automated

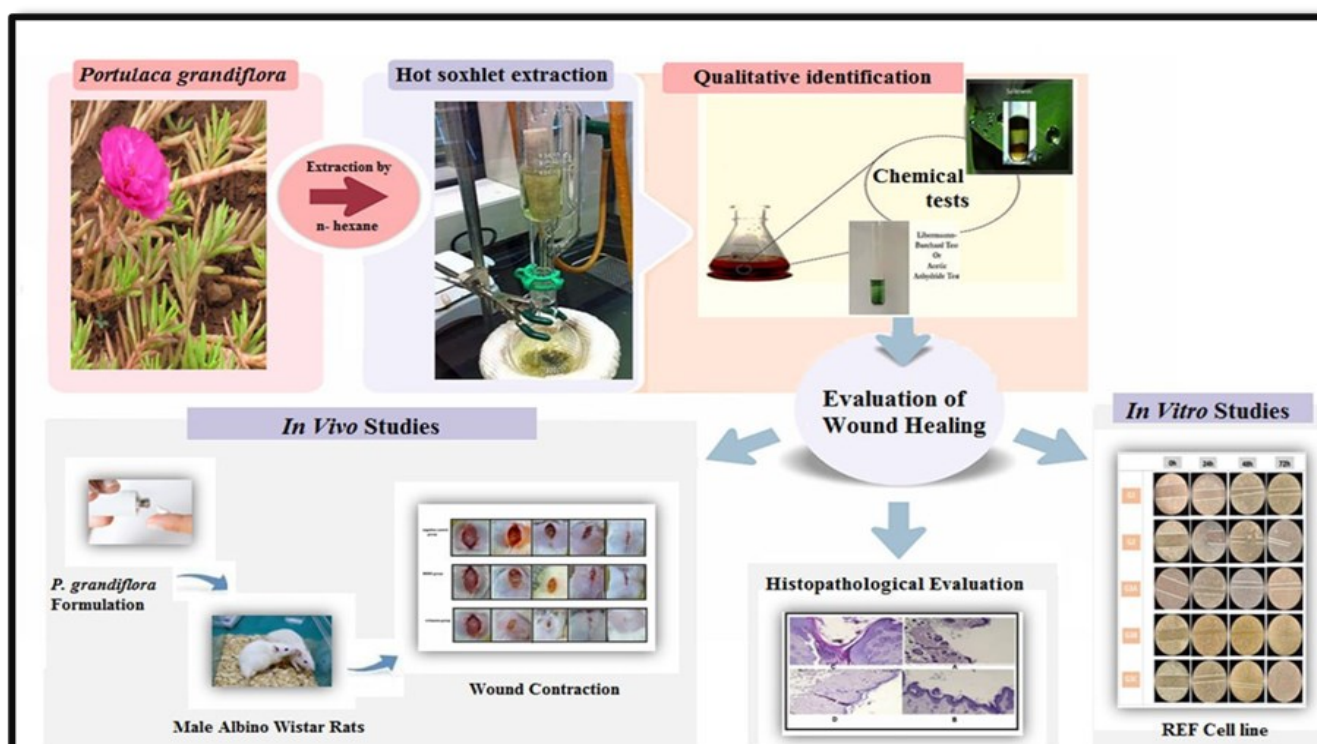


Fig 1. General scheme for *P. grandiflora* extraction, *in vivo*, and *in vitro* studies for wound healing activity.

micropipette. The plate was placed in an incubator with 5% CO<sub>2</sub> and incubated at 37°C; when a confluent monolayer was reached the n-hexane fraction was added. A pipette tip was used to scrape the cell monolayer linearly to generate a scratch, rinsing the cells once with 1 ml of the growth medium to eliminate any debris and refine the edge of the scratch. A 10mg/ml stock solution was made by diluting 10mg of n-hexane fraction with 1 ml of DMSO. From this stock solution, three doses were prepared: 100µg/ml, 50µg/ml, and 25µg/ml, which were added to the wells. MEBO ointment of 0.25% was used as a positive control. The plates were incubated at 37°C and a CO<sub>2</sub> concentration of 5%, then examined under a microscope at 0, 24, 48, and 72 hours, respectively. The dimensions of the scratch zones were evaluated using a digital image analysis tool, namely Image J software, which facilitated the calculation of the extent between the boundaries of the injuries. (20,21).

### **In Vivo study**

#### **Formulation of herbal ointment**

To make the medicated ointment, 0.1 g of n-hexane extract fraction was mixed with 40 g of petroleum jelly (white Vaseline), which is a hydrocarbon (oleaginous) base. We made the herbal ointment using the fusion procedure. We warmed the required quantity of ointment base in a water bath set at a temperature of around 50°C. By gradually adding the appropriate quantity to the melted base and swirling gently and continuously in a water bath at 40°C, a uniform dispersion was produced (22). The formulations were refrigerated and then left to reach room temperature for a duration of thirty minutes before being applied to wound treatments.

#### **Experimental animals**

A total of 18 healthy adult male Wister albino rats, weighing around 150 g and 160 g and aged around 2 months, were procured from the animal house of the College of Pharmacy at the University of Baghdad. The animals are housed in separate cages at the same location with controlled humidity, temperature, and light/dark cycle circumstances for about two weeks before the experiment. Every experimental animal had unrestricted access to water and was fed a regular diet of rodent pellets. The study procedure was approved by the University of Baghdad College of Pharmacy's local ethics committee.

#### **Grouping of animals**

Three groups of six rats each were randomly assigned to the animals:

Group I: No treatment was given to the wounds (negative control).

Group II: 0.25% MEBO ointment was applied to the wounds as a positive control.

Group III: A topical 0.25% n-hexane fraction formula was used to heal wounds.

#### **Wound excision and evaluation**

On the first day, every rat was administered anesthesia using a combination of Xylazine and Ketamine. At that juncture, the rats were maintained in a hygienic state and had their fur removed, leaving a precise measurement of 1.5 cm x 1.5 cm. A whole thickness of skin was removed to create an open. At that period, the therapeutic interventions were applied topically twice a day for a duration of 15 days. Every wound was exposed for examination and evaluation daily. The assessment areas of the surgical incision were measured on the 1st, 4th, 8th, 12th, and 16th days (23). Photos of the wound region were taken using a camera phone to monitor the recovery and closure of the wound surface. The wound area was assessed using an Ingco digital caliper tool every four days.

#### **Measurement of wound area for in vitro/in vivo studies**

The dimensions of the wounds, including their surface areas, were quantified. The wound contraction was also quantified as the percentage decrease in the initial size of the wound. The calculation of wound closure % was performed using the following equation (24).

**% Wound contraction**= (Current wound area/Wound area at the beginning) × 100

#### **Histological examination**

On the 16th day, skin samples from healed regions of rats were collected, and a (2-5) mm piece was extracted for assessment. The slices were then immersed in a 10% buffered formalin solution and underwent paraffin tissue processing using specialized equipment. They were then stained with hematoxylin and eosin for evaluation under a light microscope (25).

#### **Statistical Analysis for in vivo and vitro studies**

The data from the current research was reported as the mean, standard error of the mean (Mean ± SEM), and analyzed using SPSS (Statistical Package for Social Science) software, version 25. The statistical significance of differences across groups was assessed using two-way ANOVA. Values for P < 0.05 were considered statistically significant., it is shown by \*P < 0.05, \*\*P < 0.01, and \*\*\*P < 0.001 (26).

## **Results and Discussions**

#### **Plant extract preparation and chemical tests**


The powdered plant was extracted by n-hexane using the Soxhlet extraction technique, and the final weight obtained was 2 grams. The chemical tests done on the n-hexane fraction of *P grandiflora* showed positive results for both tests indicating the presence of steroids and terpenoids in the n-hexane fraction. The whole plant of *P. grandiflora* was extracted using the hot Soxhlet process, which relies on heat to facilitate the penetration of solvent through the plant powder. The specific method of extraction is determined by several criteria, such as the consistency and moisture level of extracting plant material, as well as the desired chemical to be separated. To maximize the extraction yield from the plant, the use of n-hexane, a nonpolar solvent, is a very effective method

for extracting nonpolar components, particularly steroids and terpenoids (14).

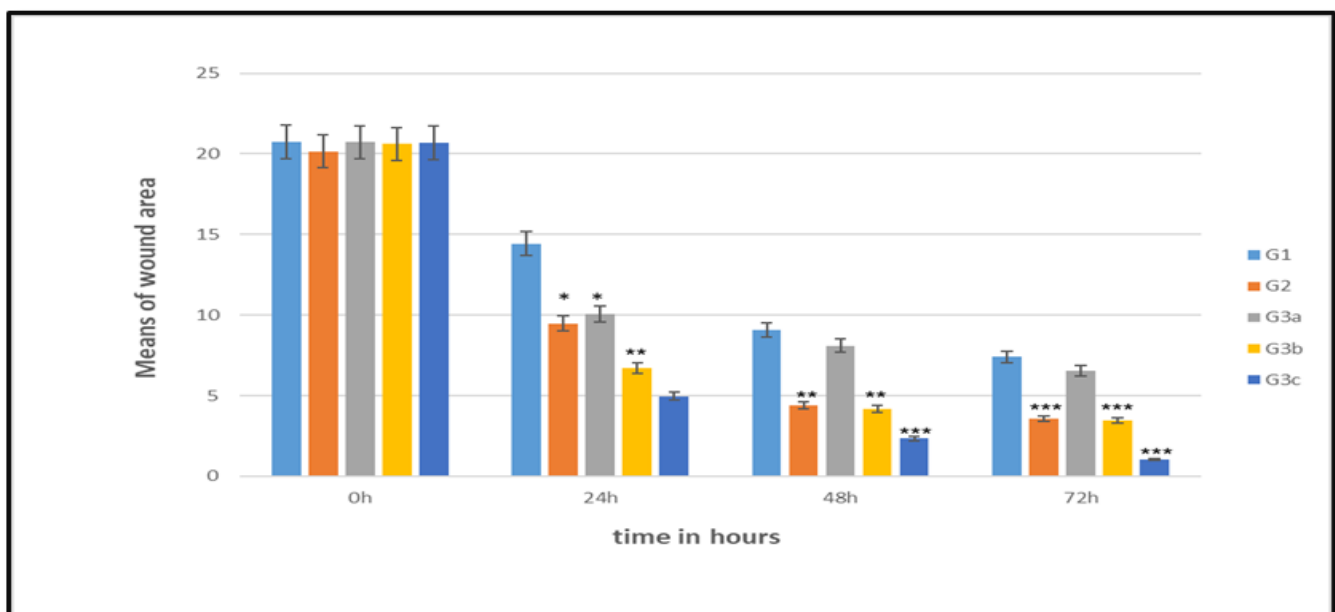
### *In-vitro* trial results

*In vitro*, Scratch Wound Assay is a simple and economical method to assess and quantify cell migration. After incubation in a medium containing 25, 50, and 100 µg /mL of *P. grandiflora* n-hexane extract. The regrowth process to seal the scratch wound was observed at 0, 24, 48, and 72 hours. The findings showed that when n-hexane extract at a concentration of 100 µg /ml was present, fibroblasts restored their complete cellular density more quickly than

in the negative and positive control groups as in Fig 2. Put simply, at every time point, the extract markedly increased the rate of fibroblast migration. This finding has important ramifications for n-hexane extract's possible ability to heal wounds. Fibroblasts have a vital function in the process of wound healing since they generate collagen and other components of the extracellular matrix. The cells treated with a concentration of 50 µg /ml of the n-hexane extract have a comparable effect to the positive control groups in promoting wound healing. Furthermore, statistically, the results show that the pace of wound closure of the treated group with 100 µg /ml of extract was noticeably quicker



**Fig 2:** Microscopical images obtained from the *in vitro* scratch wound-healing assay of n-hexane extract of *P. grandiflora* plant: images were captured at 0, 24,48, and 72 hrs (magnification:10). (G1) Negative control, (G2) MEBO treated (positive control), (G3A), (G3B) and (G3C) 25,50, and 100µg/ml of n-hexane extract.



**Fig3.** Effect of n-hexane extract of *P. grandiflora* on REF cells in a wound scratch test. The values are expressed as mean  $\pm$ S.E.M. (G1) Negative control, (G2)

than that of the negative and positive control group as demonstrated in Fig 3.

### In-vivo trial results

From a visual perspective, it was observed that the size of the wounds was reduced by an excellent percentage for n-hexane fractions compared to the negative and positive control groups, as in Fig 4.

**Group I (untreated wounds):** In this group, the first symptoms of inflammation were seen on the first day, followed by partial wound closure beginning on the fourth day and the development of scar tissue by the sixteenth day.

**Group II (wounds treated with MEBO ointment):** on day one, there were mild signs of irritation. Day 1 to Day 16 saw a modest progression of the healing process, with Day 14 seeing the creation of a tiny amount of scar tissue.

**Group III (wounds treated with the n-hexane fraction)** exhibited notable signals of wound healing starting from day 3, with the absence of any symptoms of inflammation. By the eighth day, the wound edges began to protrude. Finally, a great result was obtained on the 16th day, that the whole wound healed.

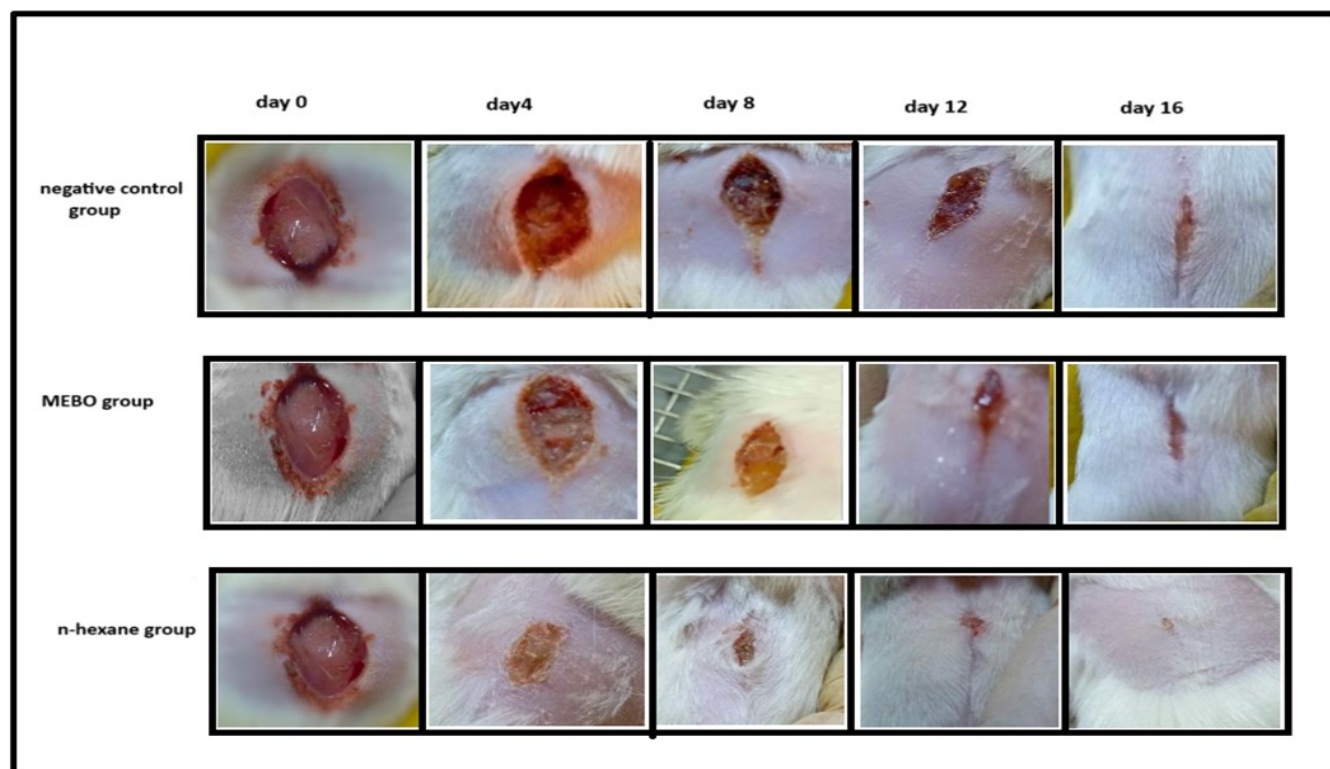
**wound contraction rate:** To assess the impact of n-hexane fractions of the *P. grandiflora* plant on the healing of excision wounds, it is necessary to quantify the size of the

wounds and the percentage of wound surface area reduction at different time points demonstrated in Table (1 and 2) and Fig (5).

The good suitability of n-hexane extract in treating wounds is due to it being rich in steroids and terpenoids, these compounds act at different phases of the healing process through different mechanisms and show anti-inflammatory, antimicrobial, and antioxidant effects, whilst promoting collagen synthesis, cell proliferation, and angiogenesis. (27)

### Histopathological analysis

**Histopathological analysis:** For the diagnosis of several infectious, degenerative, or neoplastic disorders in both people and animals, histopathology has long been the gold standard (28). Accurate evaluation of chronic wounds may provide insight into the specific disease process and aid in formulating a plan for ongoing treatment. Additionally, it may serve as a potent instrument in assessing the impact of medications on the process of wound healing (29). The proliferation process starts around three days after the onset of the initial lesion. Proliferation occurs via several phases, including angiogenesis, epithelialization, and granulation tissue creation, to restore the barrier function and defend against loss of fluid and bacterial invasion (30). On the 16th day after the surgical removal, the findings showed



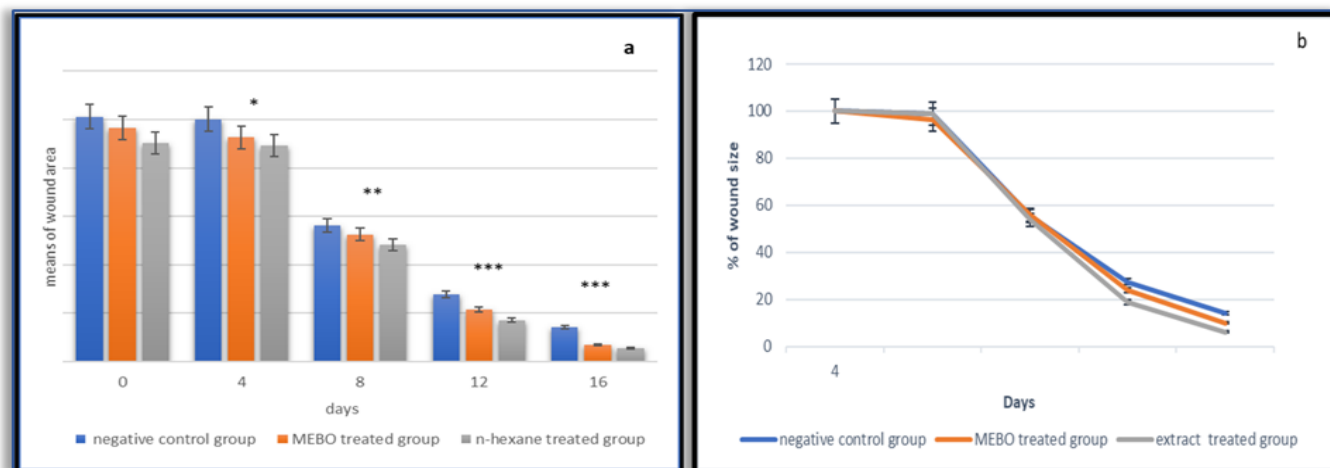
**Fig. 4.** The effect of *P. grandiflora* n-hexane extract on the reduction of wound size over an interval of time.

**Table 1.** The effect of n-hexane extract of *P. grandiflora* on excised wound areas in rats (mean  $\pm$  SEM).

Days	G1	G2	G3
	Mean of wound area $\text{cm}^2 \pm \text{S.E.M}$	Mean of wound area $\text{cm}^2 \pm \text{S.E.M}$	Mean of wound area $\text{cm}^2 \pm \text{S.E.M}$
Day 0	2.5281 $\pm$ 0.0060	2.41083 $\pm$ 0.015	2.2544 $\pm$ 0.008
Day 4	2.50158 $\pm$ 0.0039	2.314 $\pm$ 0.025	2.2318 $\pm$ 0.0035
Day 8	1.40568 $\pm$ 0.0023	1.3112 $\pm$ 0.003	1.21 $\pm$ 0.04
Day 12	0.6966 $\pm$ 0.027	0.5375 $\pm$ 0.007	0.28167 $\pm$ 0.03136
Day 16	0.355 $\pm$ 0.0076	0.1726 $\pm$ 0.013	0.12167 $\pm$ 0.00873

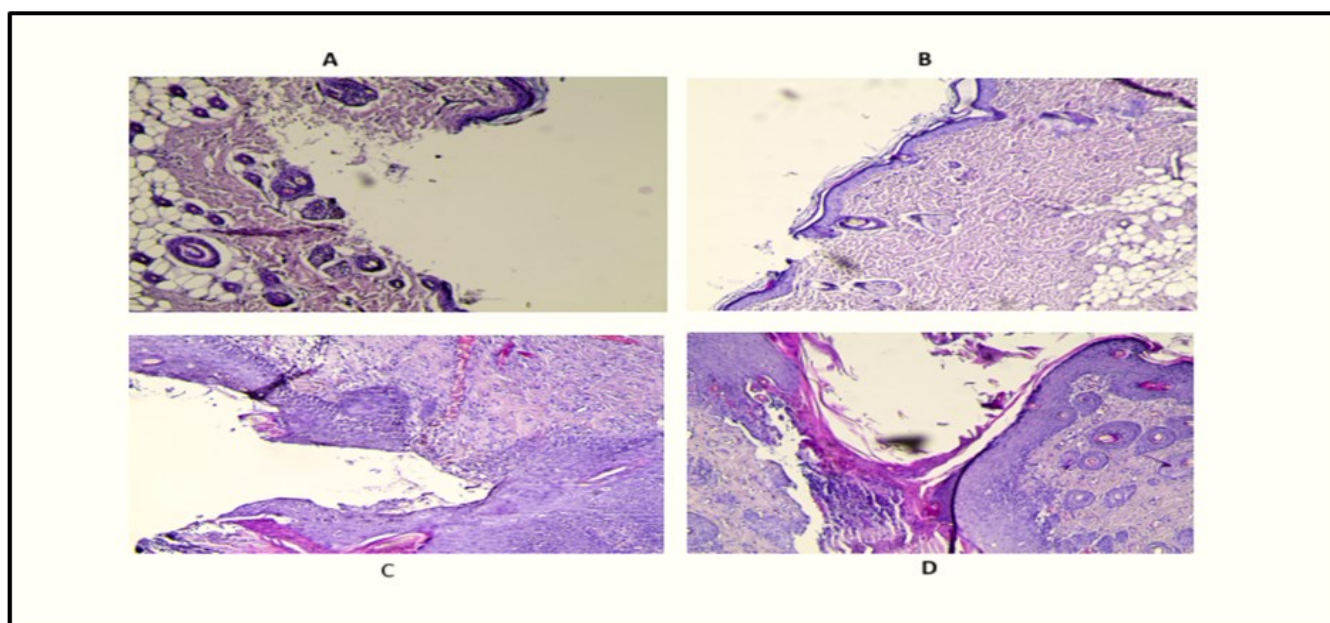
**Table 2.** The percentage of wound surface area reduction concerning the days.

Days	% of wound area contraction in G2 (Mean $\pm$ S.E.M)	% of wound area Contraction in G2 (Mean $\pm$ S.E.M)	% of wound area contraction in G3 (Mean $\pm$ S.E.M)
0	100 $\pm$ 0	100 $\pm$ 0	100 $\pm$ 0
4	98.95 $\pm$ 0.377	96.34 $\pm$ 0.451	99.003 $\pm$ 0.244
8	55.60 $\pm$ 0.198	55.73 $\pm$ 0.387	53.67 $\pm$ 2.08
12	27.54 $\pm$ 1.02	23.94 $\pm$ 0.276	12.48 $\pm$ 1.38
16	14.04 $\pm$ 0.304	10.06 $\pm$ 0.536	5.39 $\pm$ 0.391

**Fig. 5.** Effects of n-hexane extract of *P. grandiflora* on wound's evolution (a) Wound surface area means and (b) Percentage of scar tissue surface area that has healed in each cohort. All data points are expressed as the mean  $\pm$  SEM.

that the section sample of normal skin had a layered structure of epithelium and dermis, with the presence of hair follicles and sebaceous glands. The skin tissue did not show any significant abnormalities or diseases as in (Fig 6A). A histology sample of rats treated with n-hexane extract increased the average vascular density of the groups being treated, leading to enhanced healing of skin wounds. The results demonstrated full regeneration of the stratified epithelium with enhanced tensile strength. The upper dermis shows no development of scars and contains granulation tissue, which is an important sign for determining wound therapy. Additionally, there is

evidence of epidermal cell migration as in (Fig 6B). The wounds exhibited a significant increase in fibroblasts and collagen bundles compared to the positive and negative control groups (Fig 6C and D), which may be attributed to enhanced neovascularization. Therefore, it may be assumed that the group treated with the n-hexane extract showed enhanced vascular density at the wound sites in comparison to the MEBO-treated and non-treated groups. Fig 6B (slide of rats treated with n-hexane extract) exhibits a morphology closely resembling the typical Fig 6A (slide of normal skin), characterized by a smooth skin architecture Based on the findings from the tissue

**Fig. 6.** The hematoxylin and eosin staining of the post-treated group provided insights into the architecture of the skin tissue. (A) A section of normal rat skin, as determined by histology. (B) A histology sample of rats treated with n-hexane extract. (C) Histopathological slice of MEBO treated group. (D) A histology sample of the non-treated group.

samples, the rats treated with the n-hexane fraction showed improved wound healing compared to both the MEBO-treated groups and the negative control group. The wounds healed quicker and had fewer problems.

## Conclusion

Plants possess remarkable wound-healing properties and may be used in various wound models to effectively treat wounds and regulate the healing process. Therefore, herbal medications have become more popular in several nations. This study showed that n-hexane extract from *P. grandiflora* can be considered an adjuvant therapy for skin wounds due to the presence of compounds (especially steroids and terpenoids). *in vitro*, scratch wound assay shows that the n-hexane extract of *P. grandiflora* improved wound closure more rapidly than the control group. *In vivo* analyses further supported the positive effects of the plant extract on wound healing; the treated group with n-hexane extract exhibited a faster wound healing index than the control group, indicating an accelerated healing response and improved tissue regeneration. These findings imply that *p. grandiflora* possesses wound-healing abilities and may represent a viable source for extracting natural chemicals with wound-healing capabilities.

## Acknowledgements

We are grateful to the faculty and Baghdad University's staff / Pharmacy college and the Department of Pharmacognosy and Medicinal Plants for their support in providing the essential facilities.

## Authors' contributions

The authors conceived and planned the experiments and carried out the sample preparation, extraction process, identification, isolation, and Structure elucidation. The authors also wrote the manuscript.

## Compliance with ethical standards

**Conflict of interest:** Authors do not have any conflict of interest to declare.

**Ethical issues:** The experimental design and dealing with animals were conducted following the requirements outlined in the "Research Ethical Approval Form" and as per the protocol that was authorized by Baghdad University/College of Pharmacy, Baghdad, Iraq with the ethical approval number RECAUBCP12122023H.

**Did you use generative AI to write this manuscript?** No

## References

- Sullivan JV, Myers S. Skin Structure and Function, Wound Healing and Scarring. In: Plastic Surgery-Principles and Practice. Elsevier; 2022. <https://doi.org/10.1016/B978-0-323-65381-7.00001-0>
- Eming SA, Martin P, Tomic-Canic M. Wound repair and regeneration: mechanisms, signaling, and translation. *Science Translat Med.* 2014;6(265). <https://doi.org/10.1126/scitranslmed.3009337>.
- Abu-Al-Basal MA. Healing potential of *Rosmarinus officinalis* L. on full thickness excision cutaneous wounds in alloxan-induced -diabetic BALB/cmice. *J Ethnopharmacol* 2010; 131:443-450. <https://doi.org/10.1016/j.jep.2010.07.007>.
- Gushiken LFS et al. Skin wound healing potential and mechanisms of the hydroalcoholic extract of leaves and oleoresin of *Copaifera langsdorffii* Desf. Kuntze in rats. *Evidence -based Complement Altern Med* 2017; 2017:13-17. <https://doi.org/10.1155/2017/6589270>.
- Marume A, et al. Wound healing properties of selected plants used in ethnoveterinary medicine. *Front Pharmacol* 2017; 8: 1-10. <https://doi.org/10.3389/fphar.2017.00544>
- Lim CK, Tiong WN, Loo JL. Antioxidant activity and total phenolic content of different varieties of *Portulaca grandiflora*. *Int J Phytopharm.* 2014;4(1):01-5. <https://doi.org/10.7439/ijpp.v4i1.64>
- Trezzini GF, Zrýd JP. Two betalains from *Portulaca grandiflora*. *Phytochem.* 1991 ;30(6):1897-6. [https://doi.org/10.1016/0031-9422\(91\)85035-X](https://doi.org/10.1016/0031-9422(91)85035-X).
- Chavalittumrong P, Chivapat S, Attawish A, Bansiddhi J, Phadungpat S, Chaorai B, Butraporn R. Chronic toxicity study of *Portulaca grandiflora* Hook. *Journal of Ethnopharmacology.* 2004; 90(2-3):375-80. <https://doi.org/10.1016/j.jep.2003.10.018>
- Aisyah SI, Oktavia AW, Ayuningtyas AA, Putra RP, Prassiska S, Jamilah S, Nurholis W. Differences in phytochemical compounds and antioxidant activity of *Portulaca oleracea* and *Portulaca grandiflora*. *Biodiv J Bio Div.* 2023;24(3). <https://doi.org/10.13057/biodiv/d240307>
- Anghel AI, Olaru OT, Gatea F, Dinu M, Ancuceanu RV, Istudor V. Preliminary research on *Portulaca grandiflora* Hook. species (Portulacaceae) for therapeutic use. *Farmacia.* 2013;61:694-702.
- Spórna-Kucab A, Tekieli A, Grzegorzczak A, Świątek Ł, Rajtar B, Skalicka-Woźniak K, Starzak K, Nemzer B, Pietrkowski Z, Wybraniec S. Metabolite profiling analysis and the correlation with biological activity of betalain-rich *Portulaca grandiflora* Hook. extracts. *Antioxidants.* 2022;11(9):1654. <https://doi.org/10.3390/antiox11091654>.
- Shinde PR, Wagh KR, Patil PS, Bairagi VA. Pharmacognostic standardization and antibacterial potential of aerial herbs of *Portulaca grandiflora* Hooker (Portulacaceae). *World J Pharm Sci.* 2014;2:1871-85.
- Ashokkumar T, Arockiaraj J, Vijayaraghavan K. Biosynthesis of gold nanoparticles using green roof species *Portulaca grandiflora* and their cytotoxic effects against c6 glioma human cancer cells. *Env Prog Sus En.*2016; 00(00). <https://doi.org/10.1002/ep.12385>
- Streptozotocin GH. Preliminary phytochemistry and antidiabetic activity of *Portulaca grandiflora* Hook plant extract on streptozotocin-induced diabetes in rats. *Asian J Pharm Clin Res.* 2019;12(12):87-90. <https://doi.org/10.22159/ajpcr.2019.v12i12.35216>
- Rani N, Joy B, Abraham TE. Cell suspension cultures of *Portulaca grandiflora*. as potent catalysts for biotransformation of L-tyrosine into L-DOPA, an anti-Parkinson's drug. *Pharmac Bio.* 2007 1;45 (1):48-53. <https://doi.org/10.1080/13880200601026341>.
- Sarian MN, Zulkefli N, ZAIN S, Maniam S, Fakurazi S. A review with updated perspectives on *in vitro* and *in vivo* wound healing models. *Turk J Bio.* 2023;47(4):236-46. <https://doi.org/10.55730/1300-0152.2659>
- Shah SM, Abdul-Jalil TZ. Qualitative and Quantitative Estimation or Chemical Constituents from Leaves and Roots of Iraqi Agave Attenuata by GC-MS and RP-HPLC. *Iraqi J Pharm Sci.* 2022;31:75-85. <https://doi.org/10.31351/vol31issSuppl.pp75-85>

18. Mahmood MA, Abd AH, Kadhim EJ. Assessing the cytotoxicity of phenolic and terpene fractions extracted from Iraqi *Prunus arabica* on AMJ13 and SK-GT-4 human cancer cell lines. *F1000 Res.* 2023;12(433):433. <https://doi.org/10.12688/f1000research.131336.2>
19. Theeb BO, Mohammad FI, Hashim AJ, Hashim SS. Purification of hemolysin from *Aspergillus fumigatus* and study its cytotoxic effect on normal cell line (REF) *in vitro*. *Egyptian Academic Journal of Biological Sciences, G. Microbiology.* 2013;5(2):35-43. <https://doi.org/10.21608/eajbsg.2013.16637>
20. International BR. Expression of Concern on *In Vitro* Wound Healing Potential and Identification of Bioactive Compounds from *Moringa oleifera* Lam. *BioMed Res Int.* 2020;2020. <https://doi.org/10.1155/2020/8687291>.
21. Adithya RS, Manikgantan EM, Kabilan N, Kanimozhi S. *In vitro* Wound Healing Effect of a Siddha Formulation: Gandhaga Thailam. *Asian Journal of Research in Medical and Pharmaceu Sci.* 2024;13(1):77-85. <https://doi.org/10.9734/ajrimps/2024/v13i1249>
22. Laut M, Ndaong NA, Utami T. Cutaneous wound healing activity of herbal ointment containing the leaf extract of *Acalypha indica* L. on mice (*Mus musculus*). *J Phys Conf Ser* 2019; 1146:012025. <https://doi.org/10.1088/1742-6596/1146/1/012025>
23. Dons T, Soosairaj S. Evaluation of wound healing effect of herbal lotion in albino rats and its antibacterial activities. *Clin Phytosci* 2018; 4:1-6. <https://doi.org/10.1186/s40816018-0065-z>
24. Sibbald RG, Elliott JA, Persaud-Jaimangal R, Goodman L, Armstrong DG, Harley C, Coelho S, Xi N, Evans R, Mayer DO, Zhao X. Wound bed preparation 2021. *Wound Heal South Af.* 2021;14(2):52-62. <https://doi.org/10.1097/01.ASW.0000733724.87630.d6>
25. Najim SM, Fadhil AA, Abdullah MN, et al. Estimation of the healing effects of the topical use of MEBO and hyaluronic acid gel in the burned rats. *J Adv Pharm Educ Res* 2022; 12:91-97. <https://doi.org/10.51847/JO4odidwgl>
26. Shaygan S, Fakhri S, Bahrami G, et al. Wound healing potential of *Cucurbita moschata* Duchesne fruit peel extract in a rat model of excision wound repair. *Adv Pharmacol Pharm Sci* 2021; 2021:6697174. <https://doi.org/10.1155/2021/6697174>
27. Cedillo-Cortezano M, Martinez-Cuevas LR, López JA, Barrera López IL, Escutia-Perez S, Petricevich VL. Use of medicinal plants in the process of wound healing: a literature review. *Pharmaceuticals.* 2024;17(3):303. <https://doi.org/10.3390/ph17030303>
28. Karayannopoulou M, Tsioli V, Loukopoulos P, Anagnostou TL, Giannakas N, Savvas I, Papazoglou LG, Kaldrymidou E. Evaluation of the effectiveness of an ointment based on Alkannins/Shikonins on second intention wound healing in the dog. *Can J Vet Res* 2011;75:42-8. <https://doi.org/10.3390/ani14010036>
29. Lemo N, Marignac G, Reyes-Gomez E, Lilin T, Crosaz O, Ehrenfest DM. Cutaneous reepithelialization and wound contraction after skin biopsies in rabbits: a mathematical model for healing and remodelling index. *Vet Arh* 2010;80:637-52.
30. Joshi A, et al. Systematic investigation of ethanolic extract from *Leea macrophylla*: implications in wound healing. *J Ethnopharmacol* 2016; 191: 95-106. <https://doi.org/10.1016/j.jep.2016.06.034>