



RESEARCH ARTICLE

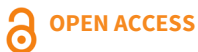# Effects of *Matricaria aurea* extract in excisional wound healing on albino rats

Sarah Hussain Khalaf<sup>1\*</sup> & Ghassan Thabet Saeed<sup>2</sup>

<sup>1</sup> Department of Pharmacology, Collage of Medicine, University of Baghdad, Baghdad, Iraq

<sup>2</sup> Department of Physiology, Collage of Medicine, University of Baghdad, Baghdad, Iraq

\*Email: [sara.ali2206m@comed.uobaghdad.edu.iq](mailto:sara.ali2206m@comed.uobaghdad.edu.iq)



## ARTICLE HISTORY

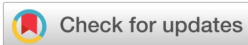Received: 12 August 2024

Accepted: 12 September 2024

Available online

Version 1.0 : 08 November 2024

Version 2.0 : 10 November 2024



## Additional information

**Peer review:** Publisher thanks Sectional Editor and the other anonymous reviewers for their contribution to the peer review of this work.

**Reprints & permissions information** is available at [https://horizonepublishing.com/journals/index.php/PST/open\\_access\\_policy](https://horizonepublishing.com/journals/index.php/PST/open_access_policy)

**Publisher's Note:** Horizon e-Publishing Group remains neutral with regard to jurisdictional claims in published maps and institutional affiliations.

**Indexing:** Plant Science Today, published by Horizon e-Publishing Group, is covered by Scopus, Web of Science, BIOSIS Previews, Clarivate Analytics, NAAS, UGC Care, etc See [https://horizonepublishing.com/journals/index.php/PST/indexing\\_abstracting](https://horizonepublishing.com/journals/index.php/PST/indexing_abstracting)

**Copyright:** © The Author(s). This is an open-access article distributed under the terms of the Creative Commons Attribution License, which permits unrestricted use, distribution and reproduction in any medium, provided the original author and source are credited (<https://creativecommons.org/licenses/by/4.0/>)

## CITE THIS ARTICLE

Khalaf SH, Saeed GT. Effects of *Matricaria aurea* extract in excisional wound healing on albino rats. Plant Science Today. 2024; 11(4): 1238–1243. <https://doi.org/10.14719/pst.4633>

## Abstract

The Asteraceae herbal plant *Matricaria aurea* (Loefl.) Sch.Bip is well known for its use in treating gastrointestinal, cardiac, pulmonary, rheumatologic and many other ailments; nevertheless, wound care has not yet received scientific validation. This study was done to evaluate the efficacy of *M. aurea* topical formulation on the rate of wound healing and contraction and the histopathological properties of the healing tissue in a rat model of an excisional wound. A total of 45 male rats with excisional wounds were enrolled in the study. The rats were divided into three groups, each with 15 male rats weighing approximately 200-250 g. The first group received treatment with *M. aurea*, the second group received fusidic acid cream and the third group received normal saline. The treatment was administered for 15 days while photographs were taken every other day, the diameters were measured and a histopathologic examination was conducted. There was a significant accelerated effect for wound healing, as evidenced by the inflammatory cells and diameters reducing to almost the same degree in the *M. aurea* and fusidic acid groups as compared to the control group ( $p < 0.05$ ). *In vivo*, the healing of wounds in albino Wister rats is demonstrated by the ethanolic extract of *M. aurea*. The findings, which show enhanced contraction, epithelization and tensile strength, significantly imply that wound healing promotion and acceleration can be achieved based on faster healing as compared to negative control and similar to standard control (fusidic acid) wounds.

## Keywords

*Matricaria aurea*; medicinal plants; fusidic acid cream; wound healing

## Introduction

The skin is the body's largest and primary protective organ, covering its entire external surface and serving as a first-order physical barrier against the environment (1). A wound is a break in the cellular and anatomical structure of body tissue, which can include deep-lying tissues, the surface of internal organs, or the skin's bodily fluid film. Cuts, slashes, scrapes, wounds that are closed, such as hematomas and wounds that are ground up can all be considered types of wounds (2).

Severe injuries, atypical metabolic processes and chronic illnesses, including diabetes and hyperglycemia, can all be factors (3, 4). The healing process consists of four separate phases: inflammation, proliferation, remodeling and coagulation and hemostasis. The procedure is dynamic. Based on the sequence of hemostasis, inflammation, proliferation and

remodeling, these phases are not distinct but rather primarily overlap (5). Medicinal plants with strong therapeutic potencies as antioxidants, antibacterial agents, analgesics, and inflammatory mediators, including those in the *Matricaria* genus (family Asteraceae), are gaining popularity (6). One of the most extensively used and extensively researched medicinal plants in Iraq and the rest of the globe is *Matricaria aurea* (Loefl.) Sch.Bip. (Asteraceae). Several commercial products, such as soaps, detergents, ointments, lotions, fragrances, baked foods, confections, alcoholic beverages and herbal teas, include *M. aurea*. *M. aurea* referred to as Baboonej locally, is found growing by the side of roads and in abandoned fields and it is extensively spread throughout the northern Iraqi mountains. Herbal remedies for several conditions, such as sore throats, chest, stomach, intestinal pain, colds and coughs, include *Matricaria aurea* are most popular these days (7). The study's objective was to find out how *M. aurea* affected the healing of wounds in male rat models using excisional wound repair.

## Materials and Methods

### Study design

Forty-five adult male Wister albino rats weighing between 200 and 250 g were utilized as the animal subjects of the current study; after getting approval from the institutional review board (IRB) of the College of Medicine/University of Baghdad (Approval No. 03-13 on 31/12/2023). They were acquired from the faculty's animal house after maturing for two months. Before the experiment, the animals were housed in separate cages at the same location with consistent lighting and dark cycles, temperature and humidity levels for around two weeks. Every test animal received the same standard mouse pellet meal and had unrestricted access to water. The rats were recognized by creating numerical markings on their bodies. Every rodent was sedated with diethyl ether on the first day. The rats were then shaved and maintained clean, measuring 1.5 cm \* 1.5 cm. Through full-thickness open extraction, a fix of skin was evacuated. On the dorsal side of 45 mature male albino rats, a full-thickness, elliptic-shaped skin wound was formed (8). The experimental rats were then grouped randomly into 3 groups. Group 1 rats (n=15) had their wounds treated with topical 2% *Matricaria aurea* cream. Group 2 rats (n=15) had their wounds treated topically with a 2% fusidic acid cream formula (Fucidin Cream 2%, Leo Pharma A/S, Ballerup, Denmark). Group 3 rats (n=15) had their wounds treated with normal saline only and acted as a control group. All topical formulations were applied three times daily and for 15 days duration. Every wound was examined every other day for two weeks. The extraction wound's estimation zones were measured (9).

### Material collection for *M. aurea*

(The Iraqi *M. aurea* plant, which is grown for its fresh takes off and lean stems, was removed from the Erbil mountains in February and April. At the University of Baghdad's College of Pharmacy). The plants were cleaned, dried in the shade at room temperature, crushed using an

electrical instrument and weighed just before extraction. For 24 h at room temperature, 200 g of finely powdered aerial parts were macerated in 150 mL of ethanol. This process was then repeated daily for three days. To create a therapeutic cream, the ethanolic extract evaporated in the rotary evaporator by reducing pressure to roughly 20 g. The dried extract was then combined with other ingredients (10, 11).

### Formulation of the herbal cream

To make the medicated cream, 0.3 g of the extract was added to the basic cold cream ingredients, which were mineral oil, paraffin wax, cetyl alcohol and beeswax. The mixture was then placed in a beaker and heated in a water bath at 70°C or 10 min. The aqueous phase was created simultaneously by mixing sterile distilled water with borax extract (*M. aurea*) in a different beaker and heating it at 70°C for 10 min. Next, when a homogeneous, smooth paste was created, the aqueous phase was gradually added to the oil phase while being continuously stirred. For later usage, the produced cream was sealed in a sterile plastic container and refrigerated between 4-8°C (12).

### Outcome measurement of wound area and contraction

To monitor the healing and constriction of the wound surface, a camera phone was used to take pictures of the area every two days. The wound area was also measured every two days by manual tracing. Both the surface areas and the morphologies of the wounds were measured and obtained. The percentage decrease in the initial size of the wound served as an expression of the wound contraction. The following equation was used to compute the percentage of wound contraction (13):

$$\% \text{ Wound contraction} = (\text{Current wound area} * 100) / (\text{Wound area at initiation}) \quad (\text{Eqn. 1})$$

### Histopathological examination

Rats' skin samples from wound-healed regions were slaughtered on days 13 and 7 and the healed skin was evaluated by removing a 5 mm<sup>2</sup> piece. After being fixed in 10% buffered formalin, the sections were run through a paraffin tissue processing machine and stained with hematoxylin and eosin so that they could be examined under a light microscope (Olympus BX51 Microscope, Olympus Corporation®, Japan) (14).

### Sample size and randomization

For sample size computation, program G Power was utilized (15), based on Cohen's principles (16). A table of random integers was used to construct the grouping based on the numerical body markings. After randomization, each group was housed in a labeled container and the rats were given tail tags to minimize misunderstandings.

### Statistical analysis

SAS was used to do the statistical analysis of the data (Statistical Analysis System, version 9.1). To evaluate significant differences between means, one- and two-factor analyses with interaction and a post hoc test for

least significant differences (LSD) were carried out. It is seemed statistically significant when  $p < 0.05$ .

**Results**

**Wound contraction rate**

Measurements of the wound's size at different times are necessary to assess the impact of *Matricaria aurea* cream on the healing of excised wounds. In comparison to the negative control group, the Matricaria cream reduces wound estimations beginning on the third postoperative day. At all times studied, the wound-healing properties of fusidic acid cream are roughly comparable to those of Matricaria cream. In the second week, the results of the Matricaria and fusidic acid cream were better than the negative control, as illustrated in Table 1 and Fig. 2.

Results revealed that the differences among mean diameters of wounds for groups were significant ( $p < 0.05$ ) for all periods except on the first day. The mean wound diameter decreased significantly along with the advanced period in the three groups. However, the rate of decrease was significantly higher in Group 2 and Group 3 as compared with the control. These results reflect the fast healing in the two groups. The healing of the wound is shown in

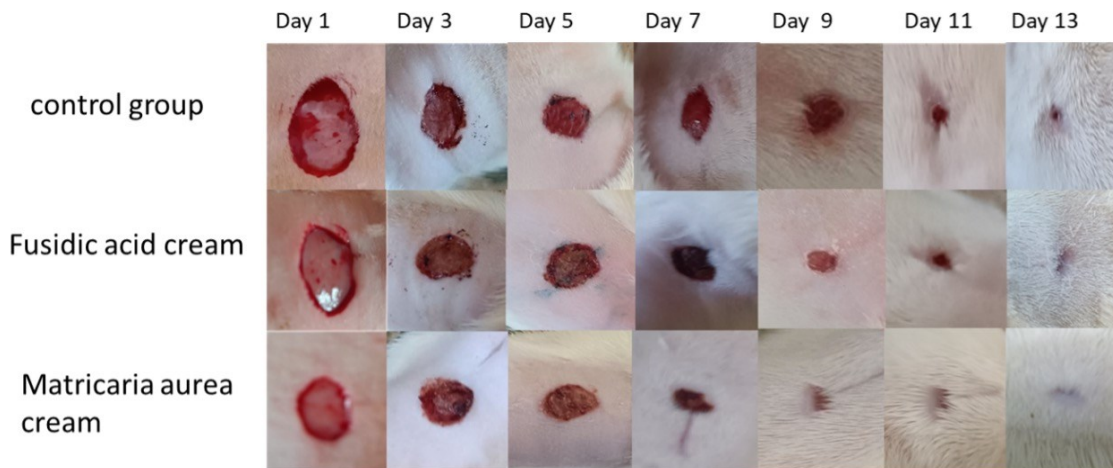
Fig. 2. To describe the prediction equations of the relationship between wound diameter and the period in rats.

Table 2 and Fig. 3 illustrate that the percentage of healing in Group 2 (91.50%) and Group 3 (91.55%) did not differ

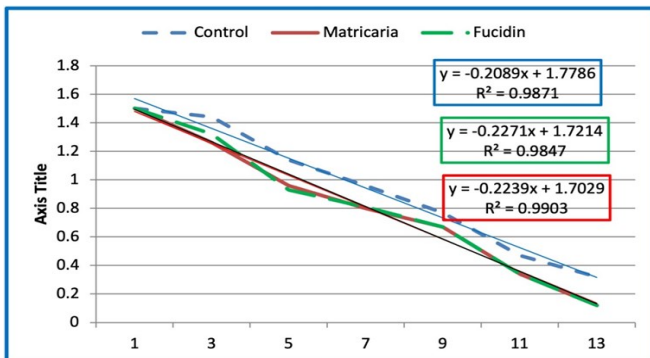
**Table 1.** The effect of the different topical preparations on wound diameters.

Groups	Days						
	1M+SD	3M+SD	5M+SD	7M+SD	9M+SD	11M+SD	13M+SD
Group 3 (Control)	A1.50 ± 0.00a	A1.44 ± 0.39a	B1.14 ± 0.116a	C0.96 ± 0.077a	D0.77 ± 0.038a	E0.47 ± 0.038a	F0.32 ± 0.038a
Group 1 ( <i>Matricaria aurea</i> )	A1.50 ± 0.00a	B1.26 ± 0.0077b	C0.96 ± 0.038b	D0.80 ± 0.038b	E0.67 ± 0.038b	F0.34 ± 0.023b	G0.12 ± 0.0193b
Group 2 (Fusidic acid)	A1.50 ± 0.00a	B1.31 ± 0.038b	C0.93 ± 0.023b	D0.81 ± 0.038b	E0.67 ± 0.031b	F0.34 ± 0.023b	G0.12 ± 0.0155b
LSD	0.05						

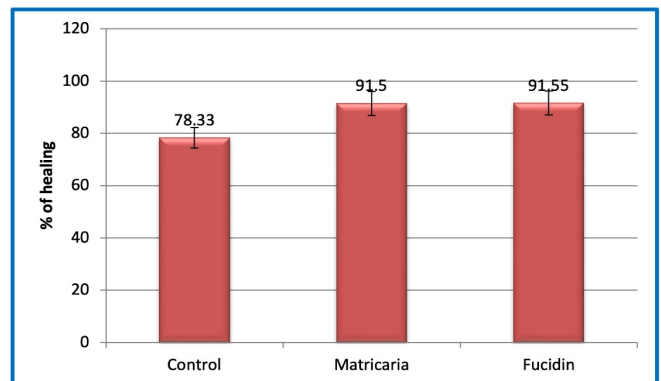
Means with a different small letter in the same column are significantly different ( $p < 0.05$ ); Means with a different capital letter in the same row are significantly different ( $p < 0.05$ ).



**Fig. 1.** Gross appearance of wound healing skin of the excised rat wound.



**Fig. 2.** The prediction equations of the relationship between wound diameter and the period in rats.



**Fig. 3.** The percentage of healing of three groups of rats.

**Table 2.** The percentage of healing after 13 days in rats.

Groups	% of healing
Group 3 (Control)	78.33 ± 0.83b
Group 1 ( <i>Matricaria aurea</i> )	91.50 ± 0.35a
Group 2 (Fusidic acid)	91.55 ± 0.31a
LSD	1.59

Means with a different letter are significantly different ( $p < 0.05$ )

significantly and in other words, the potency of *Matricaria* is similar to fusidic acid.

### Histopathological examination

On days 7 and 15, rats' skin specimens from wound-healed areas were sacrificed and the healed skin was assessed by taking a 5 mm<sup>2</sup> section and removing it. The sections were then fixed in 10% buffered formalin and processed through a paraffin tissue processing machine before being dyed with hematoxylin and eosin for examination under light microscopy (9).

#### Group 1

Regarding Group 1 treated with *M. aurea*, that illustrated in fig.4 for histological examination after 7 days the section showed the surface of stratified squamous epithelium erosion with heavy inflammatory cell infiltrations that extend to upper derms associated with granulation tissue formation. On the other hand, the section examined after 13 days showed re-epithelization of stratified squamous epithelium and the presence of granulation tissues in the upper dermis and collagen depositions.

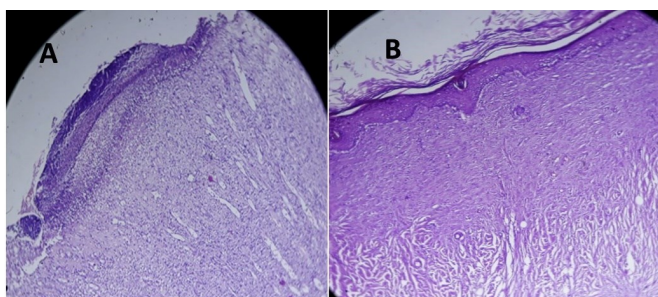
#### Group 2

Regarding Group 2 treated with fusidic acid cream, that illustrated in fig.5 for histological examination after 7 days the section showed the surface of stratified squamous epithelium erosion with heavy inflammatory cell infiltrations that extend to upper derms associated with granulation tissue formation, which involved an area more than those found in *Matricaria*. While the section examined after 13 days showed re-epithelization of stratified squamous epithelium with inflammatory cells and the presence of granulation tissues in the upper dermis and collagen depositions.

**Fig. 5.** Illustrates the histological changes for this group.

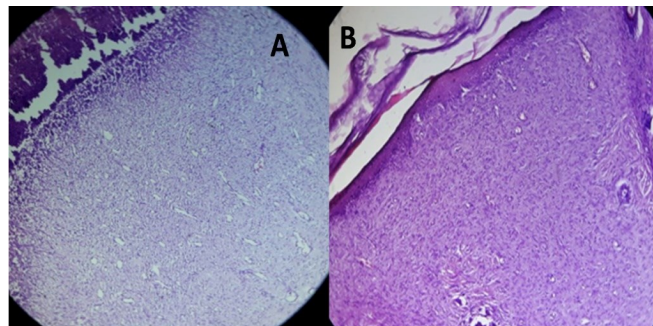
#### Group 3

Regarding Group 3 treated with normal saline, that illustrated in fig.6 as a control, the sections examined after 7 days showed surface epithelium ulcerations with heavy



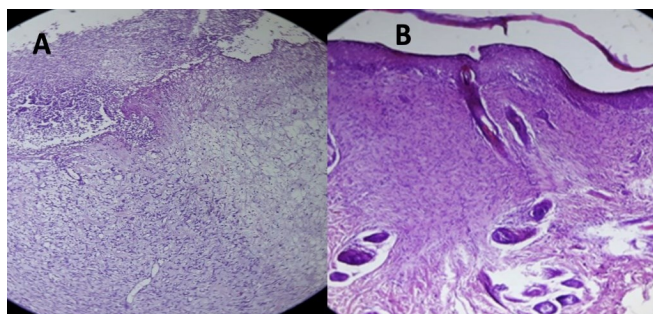
**Fig. 4.** (A) The histopathological effect of *Matricaria aurea* on the wound after 7 days of applying the cream. (B) The histopathological effect of *M. aurea* on the wound after 13 days of applying the cream.

inflammatory cell infiltrations that extend to the underlying dermis layer associated with granulation tissue formation. While the sections examined after 13 days showed re-



**Fig. 5.** (A) The histopathological effect of fusidic acid on the wound after 7 days of applying the cream. (B) The histopathological effect of fusidic acid on the wound after 13 days of applying the cream.

epithelization of stratified epithelium with infiltrating



**Fig. 6.** (A) The histopathological effect of the control group on the wound after 7 days. (B) The histopathological effect of the control group on the wound after 13 days.

inflammatory cell and the presence of granulation tissues in the upper dermis and collagen depositions.

**Fig. 6.** illustrates the histological changes for this group.

### Discussion

In this study, we use *Matricaria aurea*, which is a known local plant in the Middle East and Asia. After applying the prepared herbal cream to the induced wound and measuring the size of the wound and its general appearance, there was a significant difference among mean diameters of the wound for groups ( $p < 0.05$ ) for all periods except that of day one. The mean wound diameter decreased significantly along with the advancement of time in the three groups. However, the rate of decrease was significantly higher in Group 2 and Group 3 as compared with the control. These results reflect the faster healing in these two groups. Additionally, the measurement of wound diameters in Table 1 shows a decrease in wound diameters in groups that applied *Matricaria* and fusidic acid creams to a similar degree compared with that in the negative control group. The effect of *Matricaria* on wound diameters agrees with a study published in 2021 by (Somayeh Niknam and ...etal) that revealed the effect of *Matricaria chamomile nobel (aurea)* on accelerating wound healing by decreasing its diameters. Phytochemical examinations showed high amounts of phenolic compounds in pomegranate flowers, while chamomile flower fractions contained a high amount of total flavonoids. Both fractions, especially

pomegranate, had potent antioxidant activity. The best results for wound closure were observed 7 days after wound induction. All treated groups exhibited superior wound contraction compared to their placebo at all measurement times. The combined form of pomegranate and chamomile had better wound healing properties compared to a single therapy, especially on time earlier to wound induction (17).

That compared the effect of *Matricaria* cream and Fusidic acid cream on the percentage of wound closure that showed a non-significant difference between *Matricaria aurea* and Fusidic acid creams were 91.55% and 91.5% respectively for both herbal and chemical creams while in control it was only 78 % for the same duration. In the histopathological examination for sections treated with *Matricaria aurea* after 7 days, there was erosion on the stratified squamous epithelium tissues with heavy inflammatory cell infiltrations which extend to upper derms associated with granulation tissue formation, while in sections treated with Fusidic acid, there were increasing in the erosion area and increasing the inflammatory cells which extend to upper dermis associated with granulation tissues formation involved area more than those found in *Matricaria*, but in the section that treated with normal saline (negative group) there were ulcerations founded in the surface of epithelium with heavy inflammatory cell infiltrations which extend to the underlying dermis layer associated with granulation tissue formation. The section that used *Matricaria* cream examined after 13 days showed re-epithelization of stratified squamous epithelium and the presence of granulation tissues in the upper dermis and collagen depositions, while in the section that used Fusidin cream, there were small differences that are still a presence of the inflammatory cells and the presence of granulation tissues in the upper dermis and collagen depositions and finally the controls section showed re-epithelization of stratified epithelium with infiltrating inflammatory cell infiltrations and the presence of granulation tissues in the upper dermis and collagen depositions. Also, *Matricaria aurea* has an antioxidant effect (which protects tissues from the damaging effects of free radicals) that agreed with the study of Yousef byek F and its team published in 2022 that approved the antioxidant effect of *Matricaria aurea* in the article (Phytochemical analysis, antioxidant, cytotoxic and antimicrobial activities of golden chamomile (*Matricaria aurea* (Loefl.) Schultz Bip (18).

## Conclusion

The ethanolic extract of *Matricaria aurea* exhibits wound-healing properties *in vivo* in albino Wister rats. The results strongly suggest that wound healing promotion and acceleration can be achieved based on the effect of *M. aurea* as an anti-oxidant and anti-inflammatory that accelerates the healing when compared to negative control and similar to standard control (fusidic acid, which is derived from the microorganism *Fusidium coccineum*, is chemically a lipophilic tetracyclic triterpenoid and that means the cost of the herbal cream is less than those in

chemical cream) wounds as contraction, epithelization and tensile strength were improved. By using visible, morphometric and histological data, *M. aurea* extracts were similarly potent with standard commercially available fusidic acid cream; also the recovery time was 13 days, approximately similar to the duration of the standard interval with fusidic acid cream, giving a significant benefit over the control.

## Compliance with ethical standards

**Conflict of interest:** Authors do not have any conflict of interest to declare.

**Ethical issues:** None

## References

- Rybinski B, Franco-Barraza J, Cukierman E. The wound healing, chronic fibrosis and cancer progression triad. *Physiol Genomics* 2014; 46: 223-44. <https://doi.org/10.1152/physiolgenomics.00158.2013>.
- Dilshad S, Jalill A, Fadhil A. The Wound healing potential of Iraqi *Origanum Majorana* L n-Hexane and Ethyl Acetate fractions in a rat model of excisional wound repair: Pre-clinical test. *Journal of Research in Medical and Dental Science* 2023; 11: 237- 42.
- Mohsin Jebur MA, Hashim NG, Hamoudi Al-Obeidi SR. Mast cell, IL -1 Beta and IL-6 *Toxicology* 2020; (University of Baghdad).
- Pormohammad A, Monych N, Ghosh S, Turner D, Turner R. Nanomaterials in wound healing and infection control. *Antibiotics* 2021; 10: 473. <https://doi.org/10.3390/antibiotics10050473>
- Gushiken LFS, Beserra FP, Bastos JK, Jackson CJ and Pellizzon CH. Cutaneous Wound Healing: An Update from Physiopathology to Current Therapies. *Life (Basel)* 2021; 11 20210707.
- Ahmad I, Wahab S, Nisar N, Dera AA, Alshahrani MY, et al. Evaluation of antibacterial properties of *Matricaria aurea* on clinical isolates of periodontitis patients with special reference to red-complex bacteria. *Saudi Pharm J* 2020; 28: 1203-1209.
- Qnais EY. The analgesic effect of the ethanolic extract of *Matricaria aurea*. *Turkish Journal of Biology* 2011; 35: 347-52. <https://doi.org/10.3906/biy-0909-22>
- Alhusaynei AJ, Nayyef HD. Platelet parameters in nonthrombocytopenic preeclampsia: A Case-control study. *Journal of the Faculty of Medicine Baghdad* 2023; 65. <https://doi.org/10.32007/jfacmedbagdad.2084>
- Ayla Ş, Günal MY, Sayın Şakul AA, Biçeroğlu Ö, Özdemir EM, et al. Effects of *Prunus spinosa* L. fruits on experimental wound healing. *Medeniyet Med J* 2017; 32: 152-58. <https://doi.org/10.5222/MMJ.2017.152>
- Walia H, Kumar S and Arora S. Comparative antioxidant analysis of hexane extracts of *Terminalia chebula* Retz. Prepared by maceration and sequential extraction method. *Journal of Medicinal Plants Research* 2011; 5.
- Shareef B, Qadhi H, Ahmed S. Antioxidant effects of selenium nanoparticles prepared from eruca sativa extract on Ketoconazole -Induced testicular oxidative damage in male rats. *Journal of the Faculty of Medicine Baghdad* 2024; 66: 58-66. <https://doi.org/10.32007/jfacmedbagdad.6612174>
- Sharma G, Gadhiya J, Dhanawat M. Textbook of cosmetic formulations. Department of Pharmacy, Mewar University, Rajasthan-312 2018; 901.
- Okur ME, Ayla Ş, Çiçek Polat D, Günal MY, Yoltaş A, et al. Novel insight into wound healing properties of methanol extract of

- Capparis ovata Desf. var. palaestina Zohary fruits. J Pharm Pharmacol 2018; 70: 1401-413. <https://doi.org/10.1111/jphp.12977>
14. Najim SM, Fadhil AA, Abdullah MN, Hammodi LE. Estimation of the healing effects of the topical use of MEBO and hyaluronic acid gel in the burned rats. Journal of Advanced Pharmacy Education and Research 2022; 12: 91-97. <https://doi.org/10.51847/JO4odidwgl>
  15. Faul F, Erdfelder E, Lang AG, Buchner A. G\*Power 3: a flexible statistical power analysis program for the social, behavioral, and biomedical sciences. Behavior Research Methods 2007; 39: 175-91. 2007/08/19. <https://doi.org/10.3758/BF03193146>
  16. Charan J, Kantharia ND. How to calculate sample size in animal studies? Journal of pharmacology & pharmacotherapeutics 2013; 4: 303-06. 2013/11/20. <https://doi.org/10.4103/0976-500X.119726>
  17. Niknam S, Tofighi Z, Faramarzi MA, Abdollahifar MA, Sajadi E, et al. Polyherbal combination for wound healing: *Matricaria chamomilla* L. and *Punica granatum* L. Daru 2021; 29: 133-45. 20210509. <https://doi.org/10.1007/s40199-021-00392-x>
  18. Yousefbeyk F, Hemmati G, Gholipour Z, Ghasemi S, Evazalipour M, et al. Phytochemical analysis, antioxidant, cytotoxic and antimicrobial activities of golden chamomile (*Matricaria aurea* (Loefl.) Schultz Bip). Z Naturforsch C J Biosci 2022; 77: 331- 42. <https://doi.org/10.1515/znc-2021-0269>